


## B-MODE AND COLOR DOPPLER ULTRASONOGRAPHY OF MAMMARY TUMORS AND LOCOREGIONAL LYMPH NODES FOR CLINICAL STAGING OF MAMMARY NEOPLASMS IN BITCHES

### ULTRASSONOGRÁFIA MODO-B E DOPPLER EM CORES DOS TUMORES MAMÁRIOS E LINFONODOS LOCORREGIONAIS PARA ESTADIAMENTO CLÍNICO DAS NEOPLASIAS MAMÁRIAS EM CADELAS

### ULTRASONOGRAFÍA EN MODO B Y DOPPLER COLOR DE LOS TUMORES MAMARIOS Y LOS GANGLIOS LINFÁTICOS LOCORREGIONALES PARA EL ESTADIAJE CLÍNICO DE LAS NEOPLASIAS MAMARIAS EN PERRAS

 10.56238/revgeov17n4-020

Rejane Guerra Ribeiro Simm<sup>1</sup>, Tales Dias do Prado<sup>2</sup>, Carla Amorim Neves<sup>3</sup>, Geórgia Modé Magalhães<sup>4</sup>, Naida Cristina Borges<sup>5</sup>, Andriago Barboza de Nardi<sup>6</sup>

#### ABSTRACT

Mammary neoplasms in bitches are highly prevalent, present elevated malignancy rates, and require accurate clinical staging, particularly regarding lymph node involvement. This study aimed to evaluate the applicability of B-mode and color Doppler ultrasonography in differentiating benign and malignant mammary tumors, as well as in detecting metastasis and reactivity in locoregional lymph nodes of bitches. Thirty bitches with mammary tumors were included and allocated into three groups according to tumor size. Ultrasonographic evaluation of mammary tumors and axillary and inguinal lymph nodes was performed, followed by mastectomy and lymphadenectomy with histopathological confirmation. Clinical and ultrasonographic tumor characteristics were not able to predict malignancy ( $p = 0.99$ ). Likewise, ultrasonographic variables assessed in axillary and inguinal lymph nodes were ineffective in predicting metastasis or reactivity ( $p > 0.5$ ). Ultrasonography showed high sensitivity and negative predictive value for non-metastatic lymph nodes; however, specificity (14%) and positive predictive value (2%) were low, limiting its reliability for confirming nodal metastasis. Under the conditions of this study, B-mode and color Doppler ultrasonography alone were not reliable tools for predicting tumor malignancy or lymph node involvement, emphasizing the importance of histopathological evaluation for accurate clinical staging of canine mammary neoplasms.

**Keywords:** Clinical Staging. Diagnostic Imaging. Veterinary Oncology. Ultrasonography.

<sup>1</sup> Doctor of Veterinary Medicine. Universidade de Rio Verde (UniRV). E-mail: rejane.guerra@unirv.edu.br

<sup>2</sup> Doctor of Veterinary Medicine. Universidade de Rio Verde (UniRV). E-mail: talesprado@unirv.edu.br

<sup>3</sup> PhD in Animal Science. Universidade Federal de Goiás. E-mail: carlaamorim@ufg.br

<sup>4</sup> Doctor of Veterinary Medicine. Instituto Federal do Sul de Minas  
E-mail: georgia.magalhaes@muz.ifsuldeminas.edu.br

<sup>5</sup> Doctor of Veterinary Medicine. Universidade Federal de Goiás. E-mail: naidacborges@gmail.com

<sup>6</sup> Doctor of Veterinary Surgery. Faculdade de Ciências Agrárias e Veterinárias da Universidade Estadual Paulista (FCAV/Unesp). E-mail: andriago@fcav.unesp.br



## RESUMO

As neoplasias mamárias em cadelas apresentam elevada frequência, alto potencial de malignidade e importância prognóstica do estadiamento clínico, especialmente quanto ao envolvimento linfonodal. O presente estudo teve como objetivo avaliar a aplicabilidade da ultrassonografia em modo B associada ao Doppler em cores na diferenciação entre tumores mamários benignos e malignos, bem como na detecção de metástases e reatividade em linfonodos locorregionais de cadelas. Foram avaliadas 30 cadelas com tumores mamários, distribuídas em três grupos conforme o tamanho tumoral, submetidas a exame ultrassonográfico das mamas e dos linfonodos axilares e inguinais, seguido de mastectomia e linfadenectomia com confirmação histopatológica. As características clínicas e ultrassonográficas dos tumores não permitiram prever a malignidade ( $p = 0,99$ ). Da mesma forma, as variáveis ultrassonográficas avaliadas nos linfonodos axilares e inguinais não foram eficazes para determinar metástase ou reatividade ( $p > 0,5$ ). O exame ultrassonográfico apresentou elevada sensibilidade e valor preditivo negativo para linfonodos não metastáticos, porém baixa especificidade (14%) e valor preditivo positivo (2%), demonstrando limitação para confirmação de metástases linfonodais. Conclui-se que, nas condições deste estudo, a ultrassonografia em modo B e Doppler em cores, isoladamente, não foi confiável para prever malignidade tumoral ou envolvimento linfonodal, reforçando a necessidade da avaliação histopatológica para o estadiamento clínico preciso das neoplasias mamárias em cadelas.

**Palavras-chave:** Diagnóstico por Imagem. Estadiamento Clínico. Oncologia Veterinária. Ultrassonografia.

## RESUMEN

Las neoplasias mamarias en perras presentan alta prevalencia, elevado potencial de malignidad y gran relevancia del estadiamiento clínico, especialmente en relación con el compromiso linfonodal. El objetivo de este estudio fue evaluar la aplicabilidad de la ultrasonografía en modo B asociada al Doppler color para diferenciar tumores mamarios benignos y malignos, así como para detectar metástasis y reactividad en los ganglios linfáticos locorregionales de perras. Se evaluaron 30 perras con tumores mamarios, distribuidas en tres grupos según el tamaño tumoral, sometidas a evaluación ultrasonográfica de las mamas y de los ganglios axilares e inguinales, seguida de mastectomía y linfadenectomía con confirmación histopatológica. Las características clínicas y ultrasonográficas de los tumores no permitieron predecir la malignidad ( $p = 0,99$ ). De igual forma, las variables ultrasonográficas evaluadas en los ganglios axilares e inguinales no fueron eficaces para determinar metástasis ni reactividad ( $p > 0,5$ ). La ultrasonografía presentó alta sensibilidad y valor predictivo negativo para ganglios no metastáticos, pero baja especificidad (14%) y valor predictivo positivo (2%), lo que limita su confiabilidad para confirmar metástasis linfonodales. Se concluye que, en las condiciones de este estudio, la ultrasonografía en modo B y Doppler color, utilizada de forma aislada, no fue confiable para predecir la malignidad tumoral ni el compromiso linfonodal, reforzando la necesidad del examen histopatológico para un estadiamiento clínico preciso de las neoplasias mamarias en perras.

**Palabras clave:** Diagnóstico por Imagen. Estadiaje Clínico. Oncología Veterinária. Ultrasonografía.



## 1 INTRODUCTION

Mammary neoplasms represent one of the leading causes of morbidity and mortality in both women and female dogs, constituting a significant concern for public and veterinary health. In bitches, mammary tumors are among the most frequently diagnosed neoplasms, particularly in geriatric, intact, or late-spayed animals, and are commonly associated with high malignancy rates and metastatic potential (SORENMO et al., 2013; VÁZQUEZ et al., 2023). Beyond their clinical relevance, canine mammary tumors have been increasingly recognized as a comparative model for human breast cancer, since both species share epidemiological, histopathological, biological, and molecular similarities (KASZAK et al., 2022; NOSALOVA et al., 2024).

Clinical staging of mammary neoplasms is based on the TNM system (Tumor, Node, Metastasis), which considers the size of the primary tumor, regional lymph node involvement, and the presence of distant metastasis. This classification allows prognostic stratification and guides therapeutic decision-making, with lymph node metastasis being one of the most important predictors of survival and tumor progression (CHOCTEAU et al., 2019; VÁZQUEZ et al., 2023). Therefore, early detection of nodal metastasis plays a crucial role in surgical planning and oncologic management.

Traditionally, regional lymph nodes are assessed by palpation; however, this method has limited sensitivity and does not allow evaluation of internal nodal architecture, often leading to inaccurate interpretations. Consequently, imaging techniques have gained prominence for providing more detailed morphological and vascular assessment of these structures (FELICIANO et al., 2023).

B-mode ultrasonography is a widely available, non-invasive, and cost-effective tool that enables evaluation of size, shape, echotexture, and internal architecture of both mammary glands and regional lymph nodes. When combined with color Doppler, it also allows assessment of vascular patterns, offering additional information regarding tumor angiogenesis and malignant potential. Recent studies have demonstrated that ultrasonographic features such as heterogeneous echotexture, irregular margins, loss of nodal hilum, and increased peripheral vascularization correlate with malignancy and nodal metastasis (HILLAERT et al., 2022; ERCOLIN et al., 2024).

Furthermore, advanced ultrasonographic techniques, including contrast-enhanced ultrasonography (CEUS), elastography, and sentinel lymph node identification, have been incorporated into veterinary oncologic staging, improving diagnostic accuracy for early metastatic spread (KASZAK et al., 2022; FELICIANO et al., 2023). These advances reinforce the growing role of ultrasonography as an essential complementary tool in the clinical staging



of mammary tumors in dogs.

Therefore, the present study aimed to describe B-mode and color Doppler ultrasonographic features suggestive of locoregional lymph node metastasis and to evaluate the applicability of ultrasonography in differentiating benign and malignant mammary tumors in bitches, contributing to improved clinical staging and therapeutic decision-making.

## 2 THEORETICAL FRAMEWORK

Canine mammary tumors (CMTs) are among the most frequently diagnosed neoplasms in intact female dogs and represent one of the most relevant oncologic conditions in small animal practice worldwide. Their high prevalence, particularly in geriatric bitches, combined with considerable rates of malignancy and metastatic behavior, makes these tumors a major cause of morbidity and mortality in the canine population. Epidemiological studies consistently demonstrate that reproductive status is one of the most important risk factors, with intact or late-spayed animals presenting significantly higher incidence compared to early-ovariectomized dogs (Sorenmo et al., 2013; Vázquez et al., 2023).

Beyond their clinical importance in veterinary medicine, canine mammary tumors have gained increasing relevance as a spontaneous comparative model for human breast cancer. Several investigations have shown that both species share similar hormonal influences, histopathological classifications, molecular pathways, and metastatic patterns. This biological similarity supports the translational value of canine models for understanding tumor progression and therapeutic strategies, reinforcing the need for accurate diagnostic and staging approaches in veterinary oncology (Kaszak et al., 2022; Nosalova et al., 2024).

The clinical behavior of mammary tumors in dogs ranges from benign lesions with slow growth to highly aggressive carcinomas capable of early regional and distant metastasis. Consequently, clinical staging plays a central role in prognosis and therapeutic planning. The TNM system, which evaluates primary tumor size (T), regional lymph node involvement (N), and distant metastasis (M), remains the standard method for staging mammary neoplasms. Among these parameters, lymph node metastasis is recognized as one of the most significant prognostic indicators, directly associated with decreased survival rates and higher recurrence risk (Chocteau et al., 2019; Vázquez et al., 2023).

Regional lymph nodes, particularly axillary and inguinal nodes, constitute the first sites of metastatic dissemination for mammary carcinomas. Early identification of nodal involvement is therefore essential for determining surgical margins, selecting adjunctive therapies, and estimating prognosis. However, conventional clinical examination through palpation has important limitations, including low sensitivity, subjective interpretation, and



inability to assess internal nodal architecture. Small or early metastatic changes frequently remain undetected using this method alone (Feliciano et al., 2023).

In this context, diagnostic imaging techniques have become increasingly important in veterinary oncologic staging. Among these modalities, ultrasonography stands out as a non-invasive, widely available, and cost-effective method that can be performed in real time without ionizing radiation. B-mode ultrasonography allows detailed morphological evaluation of mammary masses and lymph nodes, including assessment of size, contour, echogenicity, echotexture, and structural organization (Hillaert et al., 2022).

Several ultrasonographic characteristics have been associated with malignancy in mammary tumors, such as irregular or spiculated margins, heterogeneous echotexture, acoustic shadowing, invasion of adjacent tissues, and increased lesion depth. Similarly, metastatic lymph nodes often demonstrate rounded shape, cortical thickening, loss of the echogenic hilum, heterogeneous parenchyma, and abnormal enlargement. These findings contribute to differentiating reactive from neoplastic changes and may support early suspicion of metastatic disease (Ercolin et al., 2024).

The addition of Doppler techniques to conventional B-mode imaging further enhances diagnostic capability by enabling vascular assessment. Tumor angiogenesis is a hallmark of malignancy, and neoplastic tissues typically exhibit increased blood flow and chaotic vascular architecture. Color and power Doppler imaging allow visualization of these vascular patterns, with malignant lesions commonly presenting peripheral or mixed vascularization, high flow signals, and reduced vascular resistance. Such hemodynamic information has been reported to correlate with tumor aggressiveness and metastatic potential (Hillaert et al., 2022).

More recently, advanced ultrasonographic modalities have been introduced into veterinary oncology. Contrast-enhanced ultrasonography (CEUS) improves visualization of microvascular perfusion, allowing more accurate differentiation between benign and malignant lesions based on enhancement patterns. Elastography, in turn, evaluates tissue stiffness, with malignant tumors generally presenting increased rigidity compared to normal or benign tissues. These complementary techniques provide functional information that may significantly improve staging accuracy (Ercolin et al., 2024).

Another important development in oncologic imaging is the concept of sentinel lymph node mapping. Identification of the first draining lymph node from the primary tumor enables targeted assessment and biopsy, increasing the likelihood of detecting early metastasis. Studies have demonstrated that ultrasonography, sometimes combined with contrast agents or other imaging modalities, can assist in locating and characterizing sentinel nodes, thereby refining locoregional staging and surgical planning (Feliciano et al., 2023; Kaszak et al.,



2022).

Despite these technological advances, there is still a need for standardized ultrasonographic criteria capable of reliably distinguishing benign from malignant mammary tumors and reactive from metastatic lymph nodes in dogs. Establishing reproducible imaging parameters may contribute to earlier diagnosis, more accurate staging, and improved therapeutic decision-making. Therefore, integrating B-mode and Doppler ultrasonography into the routine evaluation of canine mammary tumors represents a promising approach to optimize clinical outcomes and advance veterinary oncologic practice.

### **3 METHODOLOGY**

#### **3.1 ANIMALS**

All experimental procedures were approved by the Animal Use Ethics Committee (protocol no. 0003-13), Universidade de Rio Verde – GO (UNIRV). Thirty female dogs with mammary tumors were included in the study, with a mean age of  $10 \pm 1.85$  years, of different breeds, attended at the Veterinary Hospital of the School of Veterinary Medicine and Animal Science of the Federal University of Goiás (HV/EVZ/UFG).

The patients were distributed into three groups according to tumor size. When more than one mammary tumor was present, the lesion with the worst histopathological prognosis was considered.

Group 1 (G1): 10 bitches with mammary tumors smaller than 3 cm;  
Group 2 (G2): 10 bitches with mammary tumors between 3 and 5 cm;  
Group 3 (G3): 10 bitches with mammary tumors larger than 5 cm.

A questionnaire was administered to the owners in order to obtain additional information about the patients. The questions addressed tumor evolution time (slow, moderate, or rapid), performance of ovariohysterectomy, use of contraceptives, estrous cycle frequency (regular or irregular), pseudocyesis, tumor recurrence, previous breeding history, body condition score (BCS), type of diet (homemade, commercial feed, or both), and date of surgery.

The adopted body condition score was based on a five-point scale, in which grade 1 was considered cachectic, grade 2 underweight, grade 3 ideal weight, grade 4 overweight, and grade 5 obese, according to Laflamme (1997).

#### **3.2 CLINICAL STAGING OF MAMMARY NEOPLASIA**

Clinical staging was performed according to the TNM system (tumor, node, metastasis), proposed by the World Health Organization. Primary tumor size, regional lymph



node involvement, and the presence of distant metastasis were evaluated through abdominal ultrasonography and thoracic radiography in three projections (right lateral, left lateral, and ventrodorsal), following the recommendations of Lana et al. (2007).

**Table 1**

*Clinical staging classification of mammary neoplasms*

TNM CLASSIFICATION	
<b>T: primary tumor</b>	T1: less than 3 cm in diameter T2: between 3 and 5 cm in diameter T3: greater than 5 cm in diameter
<b>N: regional lymph nodes</b>	N0: no neoplastic involvement N1: neoplastic involvement present
<b>M: distant metastasis</b>	M0: absence of distant metastasis M1: presence of distant metastasis
<b>Stages</b>	I: T1, N0, M0 II: T2, N0, M0 III: T3, N0, M0 IV: any T, N1, M0 V: any T, any N, M1

Source: De Nardi et al., 2009

The anatomical location of the affected mammary gland (M1, M2, M3, M4, or M5), tumor size (less than 3 cm, 3–5 cm, or greater than 5 cm) measured with a caliper, and mass adherence (mobile, fixed to skin, or fixed to muscle) were recorded.

Axillary and inguinal lymph nodes were inspected and classified as palpable or non-palpable.

### 3.3 ULTRASONOGRAPHIC EVALUATION

Ultrasonographic examination began after trichotomy of the axillary, inguinal, and mammary tumor regions. Carbogel® acoustic gel was applied to improve contact between the skin and the transducer. All examinations were performed by a single experienced operator and were conducted prior to mastectomy and lymphadenectomy.

Animals were positioned in dorsal recumbency for the examination. A multifrequency linear and convex transducer (7.5–12 MHz) with 58% gain, coupled to a MyLab™ 30 Vet2 ultrasound device (The Esaote Group, Genova, Italy), was used.

#### 3.3.1 Mammary tumor ultrasonography

Transverse and longitudinal scans were performed according to Feliciano et al. (2012b) along the entire extension of the tumor masses to evaluate echotexture (homogeneous or heterogeneous), posterior acoustic features (none, acoustic enhancement, acoustic shadowing, or combined pattern), margin (regular or irregular), presence or absence



of calcification, and borders (well-defined or poorly defined).

Color Doppler imaging was used to evaluate tumor neovascularization (absent, mild, or marked), location (central, peripheral, or diffuse), and vascularization pattern (network, surrounding, or mosaic). After ultrasonographic examination, mammary tumors were classified as benign or malignant.

### **3.3.2 Axillary lymph node evaluation**

For identification of the axillary lymph node, the patient remained in dorsal recumbency with the thoracic limbs flexed, and the transducer was positioned in the axillary region caudal to the superficial pectoral muscle. Medial scanning allowed visualization of the axillary veins and arteries, enabling caudal identification of the axillary lymph node. Only longitudinal scans were performed due to anatomical limitations that prevented transverse imaging.

### **3.3.3 Inguinal lymph node evaluation**

For localization of the superficial inguinal lymph node, the transducer was positioned longitudinally and parallel to the inguinal mammary gland without excessive pressure on the skin. Oblique and lateral scanning movements were performed until the lymph node was located. After identification, both longitudinal and transverse scans were performed to evaluate its ultrasonographic characteristics. Only lymph nodes ipsilateral to the mammary tumors were evaluated.

Length and thickness were measured on the long axis for both axillary and inguinal nodes, while width was measured only for the inguinal node on the short axis.

Contour (regular or irregular), borders (defined or poorly defined), and shape (oval, round, or amorphous) were recorded. Shape was determined using the short-to-long axis ratio (S/L). Architecture, echotexture, and echogenicity were also evaluated.

Vascularization was assessed using power Doppler imaging, evaluating vessel quantity (mild, moderate, or high) and location (hilar, peripheral, or mixed). After ultrasonographic examination, lymph nodes were classified as metastatic or non-metastatic.

## **3.4 HISTOPATHOLOGICAL EVALUATION**

After unilateral mastectomy and ipsilateral locoregional lymphadenectomy, samples of mammary tumors and axillary and inguinal lymph nodes were fixed in 10% buffered formalin solution, sectioned at 5  $\mu$ m thickness, and stained with hematoxylin and eosin for light microscopy analysis. Diagnosis and classification of mammary tumors were performed according to Cassali et al. (2014).



### 3.5 STATISTICAL ANALYSIS

Statistical analysis was performed using Minitab 16 software (Minitab Inc., State College, PA, USA). The predictive value of each studied variable was calculated using binary logistic regression for both mammary tumors and locoregional lymph nodes. Statistical significance was set at 95% for all tests.

## 4 RESULTS AND DISCUSSION

A questionnaire was used to obtain the review and anamnesis of the patients' reproductive history. The bitches included in the study did not present significant laboratory abnormalities or radiographic findings suggestive of pulmonary metastasis that could restrict the surgical removal of mammary tumors and lymphadenectomy.

The age of bitches affected by mammary neoplasia ranged from 6 to 13 years, with a mean age of 10 years. The mean age of bitches in group 1 was 10.6 years, in group 2 was 9.2 years, and in group 3 was 10.2 years. The mean age of bitches with benign tumors was 9 years, while those with malignant tumors had a mean age of 10.07 years. These results corroborate the findings of Queiroga and Lopes (2002) and Sorenmo et al. (2011), who reported that mammary neoplasia is more frequent in geriatric bitches, particularly between 8 and 11 years of age, and rare in dogs younger than 5 years. More recent studies continue to support age as one of the main risk factors for canine mammary tumors, reinforcing the predominance of this condition in older animals (Goldschmidt et al., 2017; Sorenmo et al., 2020).

A wide variety of breeds were affected: Basset Fawn (3.33%), Boxer (3.33%), Cocker Spaniel (10%), Fila Brasileiro (10%), Fox Paulistinha (3.33%), German Shepherd (3.33%), Belgian Shepherd (6.67%), Pinscher (10%), Pit Bull (3.33%), Poodle (6.67%), Rottweiler (6.67%), Shih Tzu (3.33%), mixed-breed dogs (16.67%), and Dachshund (13.33%). These findings suggest the absence of a clear breed predisposition, as previously reported by Queiroga and Lopes (2002). However, Sorenmo et al. (2011) emphasized that miniature and toy breeds are frequently represented in epidemiological studies. According to Slecky et al. (2011), Poodles, Brittany Spaniels, Cocker Spaniels, Maltese, Yorkshire Terriers, and Dachshunds appear to have a higher predisposition to developing mammary tumors. More recent epidemiological analyses suggest that breed predisposition may be influenced by population structure and regional breed popularity, rather than a true genetic susceptibility alone (Beck et al., 2019; Sorenmo et al., 2020).

Most bitches had an ideal body condition score (66.6%), followed by underweight (16.7%) and obese (16.7%) animals. Previous studies demonstrated that young obese dogs



and those fed diets rich in red meat are statistically more likely to develop mammary tumors (Sorenmo et al., 2011). Recent evidence further supports the association between obesity, metabolic alterations, and increased mammary cancer risk, suggesting that adipose tissue-derived hormones may play a role in tumor development (Lim et al., 2016; Perez Alenza et al., 2021).

Based on reproductive history, relevant data were obtained regarding contraceptive administration, estrous cycle regularity, and spaying status. According to owners, 26.7% of the bitches had received contraceptives, and approximately 80% were not spayed. These findings are consistent with those reported by Queiroga and Lopes (2002) and Feliciano et al. (2012a), who observed a higher incidence of mammary neoplasia in non-spayed bitches and those treated with contraceptives. However, the present results differ regarding estrous cycle regularity, as 70% of the bitches in this study exhibited regular estrous cycles. Recent studies reinforce the protective effect of early ovariectomy and confirm the increased risk associated with exogenous hormone administration (Sorenmo et al., 2020; Cassali et al., 2020).

Macroscopic examination revealed that 11 tumors were located in M5 (36.7%), five in M4 (16.7%), six in M3 (20%), six in M2 (20%), and two in M1 (6.6%). Although most tumors were located in M5, no statistically significant difference was observed ( $p = 1.0$ ). According to Slecky et al. (2011), the caudal abdominal and inguinal mammary glands are the most commonly affected. Tumor size was not indicative of malignancy in the present study ( $p = 0.99$ ), contrasting with the findings of Cassali et al. (2014), who reported that tumors smaller than 3 cm in diameter are associated with a significantly better prognosis than those larger than 3 cm. Recent consensus guidelines emphasize that although tumor size is an important prognostic factor, it should be interpreted in conjunction with histological grade and lymph node involvement (Cassali et al., 2020).

Regarding adherence, 22 tumors were mobile (73%) and eight were adhered to underlying tissues (26.7%). Of the 30 tumors evaluated, six (20%) were ulcerated and 24 (80%) were non-ulcerated. The clinical characteristics assessed were not statistically significant for differentiating tumor type ( $p = 0.99$ ), although all ulcerated and adhered tumors were malignant. These findings are consistent with those reported by Lana et al. (2007) and Feliciano et al. (2012b), who stated that the absence of such clinical signs does not guarantee benignity or malignancy. Although Sorenmo (2003) reported that malignant tumors tend to be adherent and frequently ulcerated, while benign tumors are usually mobile, recent studies indicate that clinical presentation alone is insufficient for reliable differentiation, reinforcing the importance of histopathological evaluation (Goldschmidt et al., 2017; Cassali et al., 2020).



According to histological evaluation, only two tumors were benign (6.7%), whereas 28 were malignant (93.3%) (Table 2).

**Table 2**

*Absolute and percentage frequency of mammary neoplasms in bitches according to histopathological diagnosis performed at the University of Franca (UNIFRAN).*

Classificação	Frequência	Porcentagem (%)
<b>Tumor Benigno:</b>	2	6,7
-Hiperplasia celular colunares	1	3,33
-Tumor misto benigno	1	3,33
<b>Tumor Maligno</b>	28	93,3
-Carcinoma tubular	3	10
-Carcinoma <i>in situ</i> -	3	10
Carcinoma sólido	6	20
-Carcinoma papilar	3	10
-Carcinoma <i>in situ</i> misto	7	24
-Carcinossarcoma	2	6,7
-Sarcoma	2	6,7
-Carcinoma tumor misto	2	6,7
Total	30	100

Most tumors in the present study were diagnosed as carcinomas. According to Slecky et al. (2011), sarcomas are less common than carcinomas, accounting for less than 5% of all canine mammary tumors and fewer than 13% of malignant mammary tumors. More recent studies continue to confirm that carcinomas represent the predominant histological type in canine mammary neoplasia, often corresponding to more than 80% of malignant cases (Goldschmidt et al., 2017; Cassali et al., 2020; Sorenmo et al., 2020).

Ultrasonographic evaluation of the mammary glands suggested malignancy in 19 tumors (63.3%) and benignity in 11 tumors (36.7%) among the 30 bitches studied. When the ultrasonographic diagnostic impression was compared with histopathological findings, the sensitivity was calculated as 67% (19/28), specificity as 100% (2/2), positive predictive value as 100% (19/19), and negative predictive value as 19% (2/11). The ultrasonographic characteristics observed in malignant tumors are described in Table 3.

**Table 3**

*Frequency (absolute values) of ultrasonographic characteristics evaluated in B-mode in the 28 malignant tumors studied, with their respective p-values.*

Ultrasonographic characteristics	Categories	Malignant tumors (N)	p-value
<b>Calcification</b>	Present	7	<b>0,99</b>
	Absent	21	
<b>Margin</b>	Regular	7	<b>0,99</b>
	Irregular	21	



<b>Border definition</b>	Well defined	<b>16</b>	<b>0,99</b>
	Poorly defined	<b>12</b>	
<b>Echogenicity</b>	Hypoechoic	<b>9</b>	<b>0,99</b>
	Hyperechoic	<b>0</b>	
	Mixed	<b>19</b>	
<b>Acoustic shadowing</b>	Present	<b>8</b>	<b>0,99</b>
	Absent	<b>20</b>	
<b>Shadowing + enhancement</b>	Present	<b>6</b>	<b>0,99</b>
	Absent	<b>22</b>	
<b>Cavitary lesions</b>	Present	<b>10</b>	<b>0,99</b>
	Absent	<b>18</b>	

Among all ultrasonographic characteristics evaluated in the neoplastic tissue of the present study (Table 3), none effectively enabled differentiation between benign and malignant mammary tumors ( $p = 0.99$ ). These findings corroborate those of Feliciano et al. (2012b), who reported no correlation between echogenicity and margin regularity for the identification of tumor type.

In contrast to these results, several authors, including Bastan et al. (2009) and Mohammed et al. (2011), reported that benign tumors tend to present regular surfaces, whereas malignant tumors frequently exhibit irregular margins, and that heterogeneous echogenicity is indicative of malignancy. However, more recent studies emphasize that such ultrasonographic features may overlap considerably between benign and malignant lesions, limiting their diagnostic accuracy when used in isolation (Banzato et al., 2018; Burti et al., 2020).

Ultrasonographic characteristics such as calcification and posterior acoustic shadowing have been described as strong indicators of malignancy in both women and bitches (Feliciano et al., 2012b; Mohammed et al., 2011). Nevertheless, these findings were not observed in the present study, reinforcing the variability of ultrasonographic patterns in canine mammary tumors and the limited reproducibility of certain features across different populations and imaging protocols.

Color Doppler ultrasonography revealed that three of the 28 malignant tumors showed no detectable vascularization, whereas all benign tumors (two tumors) exhibited discrete, peripheral vascularization classified as “around.” Doppler ultrasonographic characteristics evaluated in this study, including vascular distribution (peripheral, diffuse, or central) and vascular pattern (around, network, or mosaic), were not determinant for malignancy ( $p = 0.99$ ). These findings are consistent with those reported by Feliciano et al. (2012b), who evaluated 60 mammary tumors in bitches and found no statistically significant association between the presence or pattern of vascularization and tumor malignancy ( $p > 0.05$ ).

The present results contradict the findings of Nyman et al. (2006), who reported a higher incidence of neovascularization in malignant tumors compared with benign ones.

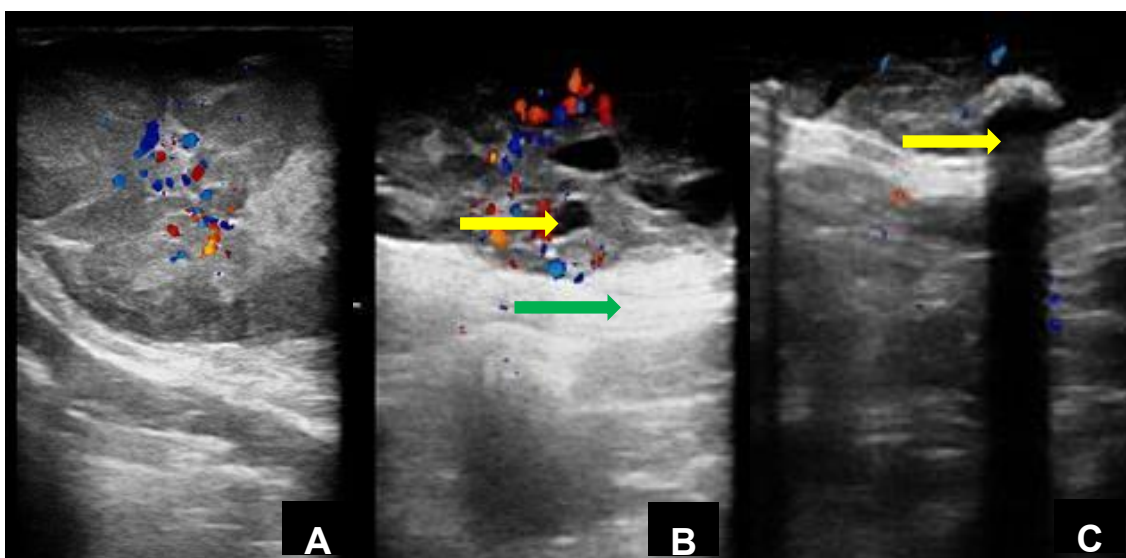


These authors also emphasized that vessel visualization depends on vessel size, which may limit the diagnostic performance of the imaging technique. In the current study, visualization of smaller vessels was feasible due to the high ultrasonographic resolution employed; however, this technological advantage did not translate into improved discrimination between benign and malignant tumors. Similar conclusions have been reported in more recent studies, which suggest that Doppler findings alone are insufficient for reliable tumor classification (Banzato et al., 2018; Burti et al., 2020).

According to Misdorp et al. (1999), malignant tumors may exhibit several features suggestive of malignancy; however, the absence of such characteristics does not exclude a malignant diagnosis. Figure 1 illustrates the ultrasonographic features observed in malignant mammary tumors in the present study.

**Figure 1**

*Ultrasonographic Doppler-mode images of malignant mammary tumors. (A) Carcinosarcoma: regular margins, well-defined borders, heterogeneous echotexture, mixed echogenicity, and moderate vascularization. (B) Carcinoma in situ, mixed tumor: irregular margins, well-defined borders, heterogeneous echotexture, mixed echogenicity, presence of cavitary areas (yellow arrow), posterior acoustic enhancement (green arrow), and marked vascularization. (C) Grade 3 solid carcinoma: regular margins, well-defined borders, heterogeneous echotexture, mixed echogenicity, presence of calcified areas with posterior acoustic shadowing (yellow arrow), and discrete vascularization.*



Source: Prepared by the authors.

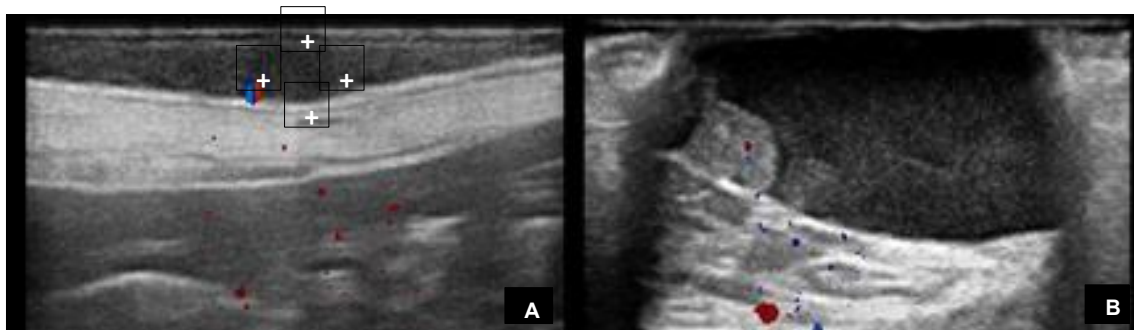
The two histologically benign tumors were located in M5; one tumor measured less than 3 cm and the other ranged from 3 to 5 cm in diameter. Both tumors were mobile, non-ulcerated, homogeneous, and hypoechoic, with well-defined borders and regular margins.



No cavitary areas, acoustic shadowing, or posterior acoustic enhancement were observed (Figure 2).

**Figure 2**

*Ultrasonographic images of benign mammary tumors. (A) Benign mixed tumor: regular margins, poorly defined borders, homogeneous and hypoechoic parenchyma, absence of posterior acoustic features and calcified areas, discrete vascularization with peripheral distribution, classified as “around.” (B) Columnar cell hyperplasia: regular margins, well-defined borders, homogeneous and hypoechoic parenchyma, absence of posterior acoustic features and calcified areas, discrete vascularization with peripheral distribution, classified as “around.”*



Source: Prepared by the authors.

The malignancy rate of 93% observed in the present study was higher than the approximately 50% reported by most authors (Ribas et al., 2012). This elevated frequency of malignancy may be associated with delayed presentation of patients to veterinary care, as benign tumors may undergo malignant transformation over time (Feliciano et al., 2012a). More recent studies reinforce that late diagnosis is a critical factor contributing to higher malignancy rates and poorer prognosis in canine mammary tumors, particularly in regions where routine screening is uncommon (Sorenmo et al., 2020; Cassali et al., 2020; Peña et al., 2021).

According to Torabi et al. (2004), lymph node evaluation should be an integral part of tumor staging, assisting in medical–surgical planning, monitoring therapeutic response, and follow-up after completion of treatment. The choice of imaging modality for lymph node assessment should consider diagnostic accuracy, cost-effectiveness, availability, and the examiner’s experience. Current oncological guidelines continue to emphasize the importance of lymph node assessment for accurate staging and prognostic stratification in canine mammary neoplasia (Cassali et al., 2020; Sorenmo et al., 2020).

The frequency of ultrasonographic characteristics was evaluated in axillary and inguinal lymph nodes using B-mode and Doppler ultrasonography. Of the 60 lymph nodes



evaluated (30 inguinal and 30 axillary), five lymph nodes were classified as metastatic by ultrasonographic examination (two axillary and three inguinal). However, only one inguinal lymph node was confirmed as metastatic by histopathological examination.

When the ultrasonographic diagnostic impression was compared with histopathological findings, the sensitivity was 100% (1/1), specificity was 14% (55/4), positive predictive value was 2% (1/5), and negative predictive value was 100% (55/55).

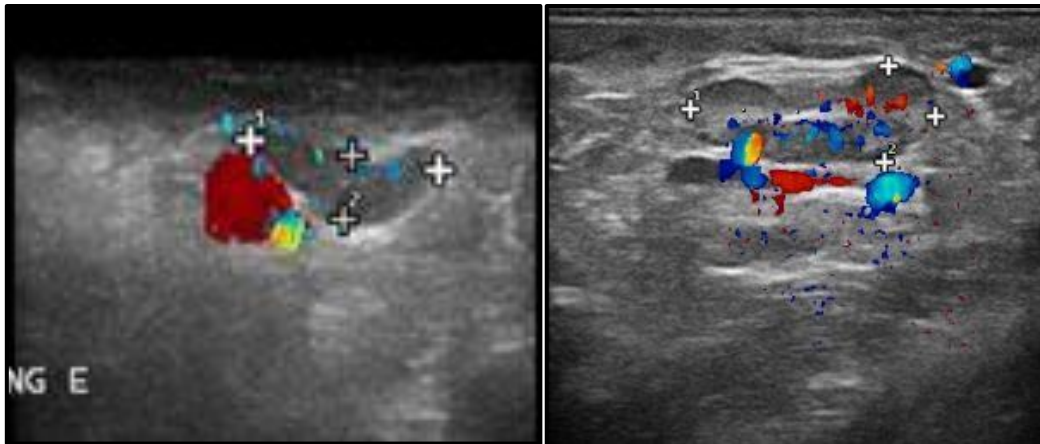
Ultrasonography alone was not able to reliably predict lymph node malignancy in this study, as metastasis was confirmed in only one inguinal lymph node and in none of the axillary lymph nodes evaluated. These findings contrast with those reported by Esen et al. (2005), who described lymph node ultrasonography as a valuable tool for differentiating benign from malignant processes. However, more recent studies highlight that ultrasonographic assessment of lymph nodes may present limited specificity, particularly in early or micrometastatic disease, reinforcing the need for histopathological confirmation (Souza et al., 2018; Burti et al., 2020; Cassali et al., 2020).

Nyman and O'Brien (2007) and Feliciano et al. (2015) described normal lymph nodes as oval, hypoechoic, and homogeneous structures with predominantly hilar or peripheral vascularization. In contrast, metastatic lymph nodes tend to be enlarged, rounded, irregularly contoured, heterogeneous, and exhibit increased and mixed vascularization (Swarte et al., 2011) (Figure 3). Recent investigations support these morphological trends but emphasize that overlap between reactive and metastatic lymph nodes may limit the diagnostic accuracy of ultrasonography when used as a sole diagnostic method (Banzato et al., 2018; Sorenmo et al., 2020).



**Figure 3**

(A) B-mode ultrasonographic image of a non-metastatic inguinal lymph node, showing irregular contour, well-defined borders, amorphous shape, disorganized architecture, homogeneous echotexture, hypoechoic echogenicity, and moderate peripheral vascularization. (B) Doppler-mode ultrasonographic image of a metastatic inguinal lymph node, showing irregular contour, well-defined borders, C/L ratio > 0.5, oval shape, preserved architecture, heterogeneous echotexture, mixed echogenicity, and marked mixed vascularization.



Source: Prepared by the authors.

A study conducted by Muramoto et al. (2011) suggests that when ultrasonographic examination in bitches with mammary neoplasia indicates the presence of lymph node metastasis, further investigation should be pursued to confirm the diagnosis. Although there is a high likelihood that the lymph node is truly metastatic, a false-positive rate of approximately 20% must be considered. Conversely, when ultrasonography suggests a non-metastatic process, the probability of misclassification is minimal, as false-negative results were reported in only 2.2%. More recent studies support these findings, emphasizing the high negative predictive value of ultrasonography for lymph node assessment, while also highlighting the limitations related to false-positive results, particularly in reactive or inflammatory lymph nodes (Banzato et al., 2018; Burti et al., 2020; Cassali et al., 2020).

Regarding the reactivity of the axillary lymph nodes evaluated in the present study, most ultrasonographic characteristics observed in B-mode and Doppler ultrasonography did not show statistical significance, as presented in Table 4. These results are consistent with recent evidence indicating that reactive lymphadenopathy may exhibit overlapping ultrasonographic features with both normal and metastatic lymph nodes, limiting the diagnostic specificity of ultrasonography when used in isolation (Souza et al., 2018; Sorenmo et al., 2020).



**Table 4**

*Ultrasonographic characteristics evaluated using B-mode and Doppler ultrasonography to determine axillary lymph node reactivity, and their respective p-values.*

<b>Ultrasonographic characteristics</b>	<b>p-value</b>
<b>Border</b>	0,999
<b>S/L ratio</b>	0,999
<b>Shape</b>	0,264
<b>Architecture</b>	0,261
<b>Echotexture</b>	0,147
<b>Echogenicity</b>	0,243
<b>Vascularization</b>	0,99
<b>Location</b>	0,99

According to the present study, the ultrasonographic feature described as irregular contour indicated reactivity in 52% of the axillary lymph nodes evaluated. Feliciano et al. (2015) reported that abnormal lymph nodes tend to maintain a regular contour; however, they may exhibit irregular contours when markedly enlarged or affected by neoplastic infiltration. More recent studies reinforce that contour irregularity alone is not a reliable indicator of lymph node pathology and may be observed in both reactive and metastatic lymph nodes, depending on the degree of enlargement and tissue remodeling (Banzato et al., 2018; Burti et al., 2020).

When palpable, the axillary lymph node, although not statistically significant, showed a tendency toward reactivity ( $p = 0.059$ ). According to Feliciano et al. (2015), palpation is possible in cases of lymphadenomegaly secondary to reactive hyperplasia of normal nodal elements, primary hematopoietic neoplasia, or metastatic disease. Recent literature supports that palpability alone should not be interpreted as a marker of malignancy, as inflammatory and reactive processes may also result in lymph node enlargement detectable on physical examination (Cassali et al., 2020; Sorenmo et al., 2020).

In the evaluation of inguinal lymph node reactivity using B-mode and Doppler ultrasonography, none of the ultrasonographic characteristics assessed indicated a reactive process, as shown in Table 5. These findings suggest that, in the present study, ultrasonographic features were insufficient to discriminate reactive changes in inguinal lymph nodes, reinforcing the need for complementary diagnostic methods for accurate lymph node characterization.



**Table 5**

*Ultrasonographic characteristics evaluated using B-mode and Doppler ultrasonography to determine inguinal lymph node reactivity, and their respective p-values.*

<b>Ultrasonographic characteristics</b>	<b>p-value</b>
<b>Contour</b>	0,24
<b>Border</b>	0,99
<b>S/L ratio</b>	0,99
<b>Shape</b>	1,0
<b>Architecture</b>	0,26
<b>Echotexture</b>	0,58
<b>Echogenicity</b>	0,52
<b>Vascularization</b>	0,35
<b>Location</b>	0,21

Palpation of the inguinal lymph node was also not significant for indicating reactivity ( $p = 0.66$ ). These findings support the limited diagnostic value of physical examination alone for assessing lymph node status, as palpability may be influenced by reactive, inflammatory, or neoplastic processes without allowing reliable differentiation among them.

Regarding clinical staging, bitches with mammary tumors smaller than 3 cm were classified as stage I, those with tumors measuring between 3 and 5 cm as stage II, and those with tumors larger than 5 cm as stage III. Only one bitch with inguinal lymph node metastasis was classified as stage IV, and no bitches were classified as stage V. According to Cassali et al. (2014), stage V is associated with the worst prognosis due to the presence of distant metastasis. More recent consensus guidelines reaffirm the prognostic relevance of clinical staging, highlighting that advanced stages, particularly stages IV and V, are strongly associated with reduced survival times in bitches with mammary neoplasia (Cassali et al., 2020; Sorenmo et al., 2020; Peña et al., 2021).

Future studies should be conducted to improve ultrasonographic techniques for better characterization of imaging features suggestive of malignancy in both tumors and lymph nodes. Such advances are essential for accurate staging of mammary neoplasms, as well as for treatment planning and prognosis estimation. Recent studies suggest that the integration of advanced Doppler techniques, contrast-enhanced ultrasonography, and multimodal imaging approaches may improve diagnostic accuracy and contribute to more precise oncological staging in veterinary medicine (Banzato et al., 2018; Burti et al., 2020; Cassali et al., 2020).

## **5 CONCLUSION**

In the present study, none of the clinical or ultrasonographic variables evaluated in mammary tumors were able to reliably predict tumor malignancy ( $p = 0.99$ ), reinforcing the



limitations of these parameters when used in isolation. Similarly, the ultrasonographic characteristics assessed were not effective in predicting the presence of metastasis in either axillary ( $p = 1.0$ ) or inguinal lymph nodes ( $p = 0.998$ ), nor were they useful for determining lymph node reactivity ( $p > 0.5$ ). Furthermore, the low specificity (14%) and positive predictive value (2%) of ultrasonography for differentiating locoregional lymph nodes as metastatic or non-metastatic in bitches with mammary neoplasia indicate that, under the conditions of this study, ultrasonography alone was not a reliable diagnostic tool for lymph node evaluation. These findings emphasize the necessity of histopathological assessment for definitive diagnosis and accurate staging, as well as the need for future studies aimed at improving imaging techniques and developing multimodal diagnostic approaches to enhance the accuracy of mammary tumor and lymph node characterization in veterinary oncology.

### ACKNOWLEDGMENTS

The authors would like to thank the University of Rio Verde (UniRV) for supporting the DINTER program in partnership with São Paulo State University (UNESP), Jaboticabal campus. We also acknowledge UNESP Jaboticabal for its institutional support and the Goiás Research Foundation (FAPEG) for providing the research scholarship.

### REFERENCES

- BASTAN, A.; ÖZENÇ, E.; PIR YAĞCI, I. Ultrasonographic evaluation of mammary tumors in bitches. *Kafkas Üniversitesi Veteriner Fakültesi Dergisi*, v. 15, p. 81–86, 2009.
- BECK, J. A. et al. Epidemiological analyses of canine mammary tumor predisposition by breed, size, and age. *Veterinary Oncology*, 2019.
- BURTI, M. et al. Ultrasonographic features and diagnostic accuracy of lymph node evaluation in canine mammary tumors. *Veterinary Radiology & Ultrasound*, 2020.
- CASSALI, G. D. et al. Consensus for the diagnosis, prognosis and treatment of canine mammary tumors. *Brazilian Journal of Veterinary Pathology*, v. 7, n. 2, p. 38–69, 2014.
- CASSALI, G. D. et al. Canine mammary tumors: update on diagnosis, prognosis and treatment. *Brazilian Journal of Veterinary Pathology*, 2020.
- DE NARDI, A. B.; RODASKI, S.; ROCHA, N. S.; FERNANDES, S. C. Neoplasias mamárias. In: DALECK, C. R.; DE NARDI, A. B.; RODASKI, S. *Oncologia em cães e gatos*. São Paulo: Roca, 2009. cap. 25, p. 372–380.
- ESEN, G. et al. Gray-scale and power Doppler US in the preoperative evaluation of axillary metastases in breast cancer patients with no palpable lymph nodes. *European Radiology*, v. 15, p. 1215–1223, 2005.



- FELICIANO, M. A. R.; CANOLA, J. C.; VICENTE, W. R. R. Diagnóstico por imagem em cães e gatos. São Paulo: Medve, 2015. cap. 22, p. 707–709.
- FELICIANO, M. A. R. et al. Estudo clínico, histopatológico e imunoistoquímico de neoplasias mamárias em cadelas. *Arquivo Brasileiro de Medicina Veterinária e Zootecnia*, v. 64, p. 1094–1100, 2012a.
- FELICIANO, M. A. R.; VICENTE, W. R. R.; SILVA, M. A. M. Conventional and Doppler ultrasound for the differentiation of benign and malignant canine mammary tumours. *Journal of Small Animal Practice*, v. 53, p. 332–337, 2012b.
- FELICIANO, M. A. R. et al. The role of ultrasonography in the evaluation of canine mammary tumors. *Animals*, v. 13, n. 11, p. 1742, 2023.
- GOLDSCHMIDT, M. H. et al. Histopathology and prognostic factors in canine mammary tumors: a contemporary review. *Veterinary Pathology*, 2017.
- HILLAERT, U. et al. Ultrasonographic and Doppler imaging features predictive of malignancy in canine mammary tumors. *Veterinary Imaging Science*, 2022.
- LAFLAMME, D. P. Development and validation of a body condition score system for dogs. *Canine Practice*, v. 22, n. 4, p. 4–15, 1997.
- LANA, S. E.; RUTTERMAN, G. R.; WITHROW, S. J. Tumors of the mammary gland. In: WITHROW, S. J.; VAIL, D. M. *Small Animal Clinical Oncology*. 4. ed. St. Louis: Saunders Elsevier, 2007. p. 619–636.
- LIM, H. K. et al. Obesity, adipokines and mammary tumor development in dogs. *Journal of Veterinary Oncology*, 2016.
- MISDORP, W.; ELSE, R. W.; HELLMÉN, E. et al. *Histological classification of mammary tumors of the dog and the cat*. 2. ed. Washington, DC: Armed Forces Institute of Pathology, 1999.
- MOHAMMED, S. I. et al. Mammography and ultrasound imaging of spontaneous canine mammary cancer and their similarities to human breast cancer. *Cancer Prevention Research*, v. 4, n. 11, p. 1790–1798, 2011.
- MURAMOTO, C. et al. Avaliação ultrassonográfica de linfonodos na pesquisa de metástase de neoplasia mamária em cadelas. *Pesquisa Veterinária Brasileira*, v. 31, n. 11, p. 1006–1013, 2011.
- NOSALOVA, N. et al. Canine mammary tumors: classification, biomarkers, and therapeutic perspectives. *International Journal of Molecular Sciences*, v. 25, n. 5, p. 2891, 2024.
- NYMAN, H. T.; O'BRIEN, R. T. The sonographic evaluation of lymph nodes. *Clinical Techniques in Small Animal Practice*, v. 22, p. 128–137, 2007.
- PEÑA, L. et al. Prognostic factors in canine mammary tumors. *Veterinary Oncology*, 2021.
- PEREZ ALENZA, M. D. et al. Metabolic and hormonal influences on canine mammary cancer. *Journal of Small Animal Practice*, 2021.



- QUEIROGA, F.; LOPES, C. Canine mammary tumours: research on new prognostic factors. *Revista Portuguesa de Ciências Veterinárias*, v. 97, p. 119–127, 2002.
- RIBAS, C. R. et al. Alterações clínicas relevantes em cadelas com neoplasias mamárias estadiadas. *Archives of Veterinary Science*, v. 17, p. 60–68, 2012.
- SORENMO, K. U. Canine mammary gland tumors. *Veterinary Clinics of North America: Small Animal Practice*, v. 33, p. 573–596, 2003.
- SORENMO, K. U.; RASOTTO, R.; GOLDSCHMIDT, M. H. Development, anatomy, histology, lymphatic drainage, clinical features and cell differentiation markers of canine mammary gland neoplasm. *Veterinary Pathology*, v. 48, p. 85–97, 2011.
- SORENMO, K. U. et al. Prognostic staging and advanced imaging in canine mammary tumors. *Veterinary Oncology Reviews*, 2020.
- SWARTE, M. et al. Comparison of sonographic features of benign and neoplastic deep lymph nodes in dogs. *Veterinary Radiology & Ultrasound*, v. 52, n. 4, p. 451–456, 2011.
- TORABI, M.; AQUINO, S. L.; HARISINGHANI, M. G. Current concepts in lymph node imaging. *Journal of Nuclear Medicine*, v. 45, p. 1509–1518, 2004.
- VÁZQUEZ, P. et al. Epidemiology and clinical behavior of canine mammary tumors. *Veterinary Cancer Journal*, 2023.

