

## GRAFTING OF BIOMODELS PRODUCED BY ADDITIVE MANUFACTURING USING ACRYLONITRILE BUTADIENE STYRENE (ABS) IN RABBIT TIBIAS

## ENXERTO DE BIOMODELOS EM ACRILONITRILA BUTADIENO ESTIRENO (ABS) PRODUZIDOS POR MANUFATURA ADITIVA EM TÍBIAS DE COELHOS

## INJERTO DE BIOMODELOS PRODUCIDOS POR MANUFACTURA ADITIVA CON ACRILONITRILLO BUTADIENO ESTIRENO (ABS) EN TIBIAS DE CONEJOS



10.56238/revgeov17n4-057

Tales Dias do Prado<sup>1</sup>, Taiane Santos Silva<sup>2</sup>, Yasmin Souza Prates<sup>3</sup>, Andressa dos Santos Honório<sup>4</sup>, Maise Medeiros Gomes da Silva<sup>5</sup>, Suzana Maira da Silva Caldas<sup>6</sup>, Marcelo Augusto Rozan dos Santos<sup>7</sup>, Tiago Luís Eilers Treichel<sup>8</sup>

### ABSTRACT

Additive manufacturing has emerged as a promising technology in the healthcare field, particularly in the development of biomodels and customized implants. This study aimed to evaluate the use of acrylonitrile butadiene styrene (ABS) biomodels produced by 3D printing as grafts in rabbit tibias. Six New Zealand rabbits were used, receiving screw-shaped implants measuring 7 mm in length. The implants were sterilized either by autoclaving or immersion in glutaraldehyde. Animals were clinically evaluated until the third postoperative day and radiographically assessed at 0, 30, and 60 days. After this period, euthanasia was performed followed by macroscopic evaluation of the implants. ABS demonstrated low tissue reactivity, absence of rejection, and signs of osteointegration. Although autoclave sterilization resulted in slight deformation, it did not impair implantation. These findings suggest that ABS has potential for use in the development of customized orthopedic implants, although further long-term studies are required.

**Keywords:** Biomodels. Bone Implants. Polymers. Rabbits. 3D printing.

### RESUMO

A manufatura aditiva tem se destacado como uma tecnologia promissora na área da saúde, especialmente no desenvolvimento de biomodelos e implantes personalizados. O presente estudo teve como objetivo avaliar a utilização de biomodelos em acrilonitrila butadieno

<sup>1</sup> Dr. in Veterinary Medicine. Universidade de Rio Verde (UniRV). E-mail: talesprado@unirv.edu.br

<sup>2</sup> Veterinary Medicine Student. Universidade de Rio Verde (UniRV). E-mail: sstaiane@gmail.com

<sup>3</sup> Veterinary Doctor. Universidade de Rio Verde (UniRV). E-mail: yasminsprates@academico.unirv.edu.br

<sup>4</sup> Veterinary Medicine Student. Universidade de Rio Verde (UniRV).

E-mail: andressasantoshonorio@gmail.com

<sup>5</sup> Veterinary Doctor. Universidade de Rio Verde (UniRV). E-mail: maise.m.g.silva@academico.unirv.edu.br

<sup>6</sup> Veterinary Doctor. Universidade de Rio Verde (UniRV). E-mail: suzanamsaldas@gmail.com

<sup>7</sup> Dr. in Mechanical Engineering. Universidade de Rio Verde (UniRV).

E-mail: arquiteturaurbanismo@unirv.edu.br

<sup>8</sup> Dr. in Veterinary Medicine. Universidade de Rio Verde (UniRV). E-mail: tiago@unirv.edu.br



estireno (ABS), produzidos por impressão 3D, como enxertos em tíbias de coelhos. Foram utilizados seis coelhos da raça Nova Zelândia, nos quais foram implantados dispositivos em formato de parafusos com 7 mm de comprimento. Os implantes foram esterilizados por autoclave ou por imersão em glutaraldeído. Os animais foram avaliados clinicamente até o terceiro dia pós-operatório e radiograficamente aos 0, 30 e 60 dias. Após esse período, foi realizada a eutanásia e avaliação macroscópica dos implantes. Observou-se que o ABS apresentou baixa reatividade tecidual e ausência de sinais de rejeição, com evidências de osteointegração. Embora a esterilização em autoclave tenha causado leve deformação dos implantes, não houve comprometimento da implantação. Os resultados indicam que o ABS apresenta potencial para aplicação na produção de implantes ortopédicos personalizados, sendo necessários estudos adicionais para avaliação a longo prazo.

**Palavras-chave:** Biomodelos. Coelhos. Implantes Ósseos. Impressão 3D. Polímeros.

## RESUMEN

La manufactura aditiva ha surgido como una tecnología prometedora en el área de la salud, especialmente en el desarrollo de biomodelos e implantes personalizados. El presente estudio tuvo como objetivo evaluar el uso de biomodelos de acrilonitrilo butadieno estireno (ABS), producidos mediante impresión 3D, como injertos en tibias de conejos. Se utilizaron seis conejos de la raza Nueva Zelanda, en los cuales se implantaron dispositivos en forma de tornillos de 7 mm de longitud. Los implantes fueron esterilizados mediante autoclave o por inmersión en glutaraldeído. Los animales fueron evaluados clínicamente hasta el tercer día postoperatorio y radiográficamente a los 0, 30 y 60 días. Posteriormente, se realizó la eutanasia y la evaluación macroscópica de los implantes. El ABS presentó baja reactividad tisular, ausencia de rechazo y evidencias de osteointegración. Aunque la esterilización por autoclave causó una ligera deformación, no comprometió la implantación. Los resultados indican que el ABS tiene potencial para su aplicación en implantes ortopédicos personalizados, siendo necesarios estudios adicionales a largo plazo.

**Palabras clave:** Biomodelos. Conejos. Implantes Óseos. Impresión 3D. Polímeros.



## 1 INTRODUCTION

The search for new technologies involving different materials and manufacturing processes has increasingly gained space in both scientific research and the market, whether in industry, communication, art, and more recently, in the healthcare field, with applications in surgical planning, prosthesis development, anatomy teaching, and implant production (SILVA; KAMINSKI, 2008). This technological advancement is directly related to the growing demand for greater precision, customization, and efficiency in both production and therapeutic processes (GIBSON; ROSEN; STUCKER, 2015).

In addition, there is an increasing concern regarding the development of sustainable technologies that minimize environmental impact and material waste. In this context, additive manufacturing stands out for using only the necessary amount of material during fabrication, unlike traditional subtractive methods (SALCHER et al., 2013; GEBHARDT, 2012). This characteristic makes it particularly attractive from both environmental and economic perspectives.

Additive manufacturing (AM), also known as rapid prototyping, comprises a group of technologies capable of producing three-dimensional objects through the successive deposition of material layers based on digital models (VOLPATO; CARVALHO, 2007; SANTOS et al., 2018). According to Gibson, Rosen, and Stucker (2015), this process allows a high degree of geometric freedom, enabling the fabrication of complex structures that would be difficult or impossible to achieve using conventional methods.

In addition to CAD-generated models, AM can also utilize data obtained from three-dimensional scanning techniques, such as computed tomography and laser scanning, within the framework of reverse engineering (RAULINO, 2011; CHUA; LEONG; LIM, 2010). This significantly expands its applications, particularly in the biomedical field, where customization is a critical factor for therapeutic success.

Three-dimensional printing technology eliminates the need for molds and specific tooling, reducing production steps and allowing direct fabrication of final products. Furthermore, the technology itself can generate support structures during the printing process, which are later removed, facilitating the construction of complex geometries (RAULINO, 2011; GEBHARDT, 2012).

Currently, several additive manufacturing systems are available on the market, all based on the same principle of layer-by-layer fabrication, but utilizing different materials such as polymers, metals, and ceramics. These systems were initially developed for industrial applications with the aim of reducing production time, improving quality, and lowering costs, and were later incorporated into the healthcare field (GIBSON; ROSEN; STUCKER, 2015).



In medicine, the use of additive manufacturing has revolutionized surgical planning by enabling the creation of three-dimensional anatomical models from imaging modalities such as computed tomography (CT) and magnetic resonance imaging (MRI) (LIMA, 2009). These models provide improved visualization of anatomical structures and support clinical decision-making (RENGIER et al., 2010).

Moreover, the conversion of medical imaging data into three-dimensional models allows the fabrication of highly accurate biomodels, contributing to the development of customized prostheses, surgical guides, and implants (MATOZINHOS et al., 2017; VENTOLA, 2014). These applications have demonstrated significant benefits, including reduced surgical time and improved clinical outcomes.

In veterinary medicine, the application of these technologies has also grown considerably, especially in orthopedics and traumatology. The use of biomodels enhances surgical planning and increases procedural predictability, contributing to better clinical outcomes (OSORIO et al., 2018).

With ongoing research advancements, new therapeutic possibilities are being explored, including the use of 3D printing for the production of biological structures and personalized devices. Some authors suggest that, in the future, it may be possible to fabricate tissues and organs using the patient's own cells, thereby reducing the risk of immune rejection (BARRETO et al., 2018; MURPHY; ATALA, 2014).

In terms of materials, polymers play a fundamental role in additive manufacturing. Natural polymers are those formed during the life cycle of living organisms (FRANCHETTI; MARCONATO, 2006), whereas biopolymers are derived from renewable resources such as corn, sugarcane, cellulose, and chitin (BRITO et al., 2011). These materials have been widely studied due to their biodegradability and reduced environmental impact.

Historically, humans have used natural polymers such as wool, leather, and natural rubber to produce everyday materials (BROWN et al., 2005). However, with industrial advancement, synthetic polymers have gained prominence due to their versatility and superior mechanical properties (CALLISTER; RETHWISCH, 2016).

Among synthetic polymers used in additive manufacturing, acrylonitrile butadiene styrene (ABS) stands out as a widely used thermoplastic due to its favorable mechanical and thermal properties. ABS exhibits high impact resistance, good dimensional stability, low moisture absorption, and ease of processing, making it suitable for use in fused deposition modeling (FDM) 3D printing (CHUA; LEONG; LIM, 2010; CALLISTER; RETHWISCH, 2016).

Furthermore, ABS presents characteristics that support its application in biomedical devices, such as adequate mechanical strength and the ability to be shaped into complex



structures. However, its biocompatibility remains under investigation, particularly for implantable applications (VENTOLA, 2014).

Given this context, it is essential to investigate the behavior of biomodels produced by additive manufacturing when implanted into biological tissues. Evaluating the biological response, including immune rejection and tissue integration, is crucial to determine the feasibility of these materials for clinical applications.

Thus, the present study aimed to evaluate the use of acrylonitrile butadiene styrene (ABS) biomodels produced by additive manufacturing as grafts in rabbit tibias, analyzing their biological resistance and immune response, with the perspective of future application in the development of easily accessible customized prostheses and orthoses.

## **2 METHODOLOGY**

### **2.1 ETHICAL APPROVAL**

This study was approved by the Animal Ethics Committee (CEUA) of the University of Rio Verde (UniRV) and conducted in accordance with the ethical principles established by the Brazilian College of Animal Experimentation (COBEA), under protocol number 09/21

### **2.2 ANIMALS**

Six New Zealand rabbits (*Oryctolagus cuniculus*), approximately six months old and weighing around 3.5 kg, of both sexes, were used in this study. The animals were obtained from the rabbit breeding sector of UniRV and underwent a one-week acclimatization period, during which their general health status was monitored.

They were housed individually in cages under controlled environmental conditions, including adequate hygiene, temperature, lighting, and protection from weather conditions. Environmental enrichment was provided using hanging chains to minimize stress.

The animals were fed a commercial diet supplemented with carrot, hay, and kale, with water provided ad libitum. An 8-hour fasting period was implemented prior to the surgical procedure. After surgery, the animals were maintained under the same conditions for eight weeks.

### **2.3 IMPLANT FABRICATION**

The implants were manufactured using a Zonestar DIY 802QR2 3D printer, equipped with dual extrusion nozzles with X–Y axis movement and a heated print bed with Z-axis movement.



The fused deposition modeling (FDM) technique was employed, using acrylonitrile butadiene styrene (ABS) filament. The implants were designed and printed in the form of screws measuring 7 mm in length.

## 2.4 IMPLANT STERILIZATION

Two sterilization methods were used. For the first group, implants were packaged in surgical-grade paper and sterilized in an autoclave at 160°C for 30 minutes.

For the second group, implants were immersed in glutaraldehyde solution for 8 hours. Prior to implantation, the materials were rinsed with sterile distilled water to minimize potential tissue toxicity.

## 2.5 PREOPERATIVE PROCEDURES AND ANESTHETIC PROTOCOL

After confirmation of clinical health status, animals underwent wide trichotomy in the medial metaphyseal region of both tibias, as well as in the auricular region for access to the caudal auricular vein. Body weight was recorded using a digital scale with 1g precision one day prior to surgery.

Animals were then referred to the surgical center of the Veterinary Hospital for Small Animals at UniRV.

The anesthetic protocol consisted of intramuscular administration of acepromazine (0.05 mL/kg), tramadol hydrochloride (3 mg/kg), midazolam (0.2 mg/kg), and ketamine (22 mg/kg), followed by local infiltrative anesthesia using 0.4 mL of 2% lidocaine.

During the procedure, animals were monitored continuously and received 100% oxygen via an oronasal mask. Anesthesia was maintained with isoflurane at an initial concentration of 2.5%, adjusted as needed.

## 2.6 SURGICAL PROCEDURE

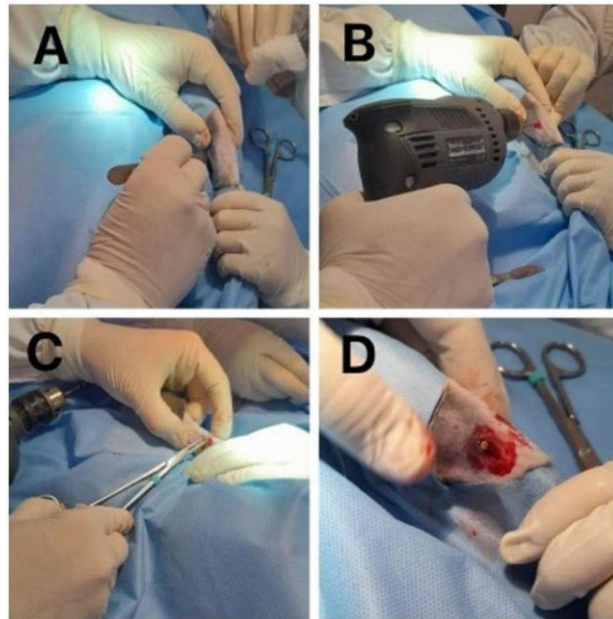
After achieving an adequate anesthetic plane (Guedel stage III, plane 3), antisepsis of the surgical site was performed using two applications of 2% chlorhexidine gluconate followed by 70% alcohol, and final antisepsis with three additional applications of 70% alcohol. The surgical field was then draped using sterile fenestrated drapes.

A skin incision of approximately 3 cm was made using a size 21 scalpel blade, followed by blunt dissection of the subcutaneous tissue using Metzenbaum scissors. A longitudinal incision was then made in the periosteum to expose the proximal medial metaphyseal cortex of the tibia (Figure 1).



**Figure 1**

*A – Skin incision made with a scalpel. B – Bone drilling conducted with surgical drills. C – Implant placement with manual stabilization. D – Implant positioned and fixed in bone tissue.*



Source: Prepared by the authors.

A bone perforation measuring 7 mm in depth and 2 mm in diameter was created using surgical drills under high-speed rotation with continuous irrigation using sterile saline solution.

The implants were manually inserted and stabilized using Kocher forceps. After implantation, muscular fascia was sutured using absorbable Vicryl 5-0, and the skin was closed using nylon 4-0. Implants placed in the right tibias were sterilized by autoclave, while those in the left tibias were sterilized using glutaraldehyde.

## 2.7 POSTOPERATIVE CARE

After surgery, the animals were monitored until full recovery from anesthesia and then returned to their housing.

Postoperative medication included enrofloxacin (5 mg/kg, once daily for 7 days), tramadol hydrochloride (3 mg/kg, three times daily for 3 days), and meloxicam (0.1 mg/kg, once daily for 4 days), all administered subcutaneously.

Surgical wounds were cleaned daily using sterile saline solution and treated with rifamycin spray. After the third postoperative day (D3), no further clinical alterations were observed, and handling was minimized to reduce stress.



## 2.8 CLINICAL EVALUATION

Implant sites were clinically evaluated up to the third postoperative day (D3). Edema was assessed using a binary scoring system: score 0 for absence of edema and score 1 for presence of edema

## 2.9 RADIOGRAPHIC EVALUATION

Pelvic limbs were evaluated radiographically every 30 days after surgery (D0, D30, and D60), totaling three evaluations per animal. Since radiographic findings were homogeneous across all treatments and replicates, statistical analysis was not performed for this parameter.

## 2.10 EUTHANASIA AND IMPLANT EVALUATION

After 60 days, animals were euthanized using an overdose of ketamine administered intravenously via the caudal auricular vein, followed by potassium chloride administration. Vital parameters, including heart rate, respiratory rate, and pulse, were monitored to confirm death. Following confirmation, tibias were collected and individually stored in 10% formalin for subsequent analysis

## 2.11 STATISTICAL ANALYSIS

A completely randomized design was used, with two treatments and six replicates. The treatments consisted of implant sterilization by autoclave or glutaraldehyde, and each animal represented one experimental unit. Data obtained were subjected to analysis of variance (ANOVA) using the F-test at a 5% significance level.

## 3 RESULTS AND DISCUSSION

The implants sterilized by autoclaving showed slight deformation when compared to the original printed prototypes. This finding represents a potential limitation, as one of the main advantages of additive manufacturing is the ability to produce customized implants with high dimensional accuracy. Despite this alteration, no difficulty was observed during implant insertion into the bone tissue.

Thermal sterilization methods, such as autoclaving, are known to affect the structural integrity of thermoplastic polymers, including acrylonitrile butadiene styrene (ABS), due to their sensitivity to high temperatures (GEBHARDT, 2012; CALLISTER; RETHWISCH, 2016). This may explain the observed deformation and highlights the importance of selecting appropriate sterilization techniques for polymer-based implants. In contrast, implants



sterilized using glutaraldehyde maintained their structural characteristics, suggesting that chemical sterilization may be more suitable for preserving the integrity of additively manufactured ABS components. The choice of sterilization method is a critical factor in determining the performance and biocompatibility of implanted biomaterials (SEHLINGER et al., 2015).

Regarding clinical evaluation, although four out of six implants sterilized with glutaraldehyde presented edema at the incision site, no statistically significant difference was observed between the treatments at the 5% significance level. These findings suggest that both sterilization methods are comparable in terms of short-term inflammatory response.

Postoperative radiographic evaluations performed at 0, 30, and 60 days revealed homogeneous results among all animals, indicating consistent implant positioning and absence of apparent complications such as displacement or severe bone reaction. Radiographic analysis is widely recognized as an effective method for assessing bone healing and the performance of biomaterials in vivo (SILVA et al., 2003).

Macroscopic evaluation of the tibias after euthanasia demonstrated no evidence of implant rejection. Additionally, signs of osteointegration were observed in all animals, indicating a favorable biological response to the implanted material.

These results are consistent with previous studies that reported fibrovascular infiltration and good biocompatibility of polymer-based implants, supporting their use in reconstructive procedures (GOMES JÚNIOR et al., 2016). The absence of significant adverse reactions suggests that ABS may be considered a promising material for orthopedic applications, particularly when used in customized implants produced by additive manufacturing.

Furthermore, the low tissue reactivity observed in this study reinforces findings from previous research indicating that certain synthetic polymers can exhibit acceptable biological behavior when properly processed and sterilized (VENTOLA, 2014).

Taken together, the results demonstrate that additive manufacturing using ABS can produce implants with adequate mechanical and biological performance for experimental orthopedic applications. However, the choice of sterilization method plays a crucial role in maintaining implant integrity and should be carefully considered in future applications.

#### **4 CONCLUSION**

This study demonstrated that biomodels produced by additive manufacturing using acrylonitrile butadiene styrene (ABS) can be successfully applied as bone implants in rabbit tibias, showing satisfactory biological performance. The absence of rejection and the



presence of osteointegration indicate that ABS is a promising material for orthopedic applications.

Although autoclave sterilization caused slight deformation, it did not impair implantation or short-term outcomes. In contrast, glutaraldehyde preserved implant integrity, highlighting the importance of selecting appropriate sterilization methods for polymer-based biomaterials.

Overall, the findings support the feasibility of using ABS for the development of low-cost, customized implants. However, further studies are needed to evaluate long-term behavior and histological responses.

### ACKNOWLEDGMENTS

The authors would like to thank the University of Rio Verde (UniRV) for the opportunity provided through its Scientific Initiation Program, as well as for the infrastructure and continuous support throughout the development of this study.

### REFERENCES

- Barreto, B. L., et al. (2018). A importância das impressoras 3D na medicina. *Universo Recife*, 5(2), 1.
- Brito, G. F., et al. (2011). Biopolímeros, polímeros biodegradáveis e polímeros verdes. *Revista Eletrônica de Materiais e Processos*, 6(2), 127–139.
- Brown, T. L., et al. (2005). *Chemistry: The central science* (10th ed.). Upper Saddle River: Pearson Prentice Hall.
- Callister, W. D., & Rethwisch, D. G. (2016). *Materials science and engineering: An introduction* (9th ed.). New York: Wiley.
- Chua, C. K., Leong, K. F., & Lim, C. S. (2010). *Rapid prototyping: Principles and applications* (3rd ed.). Singapore: World Scientific.
- Franchetti, S. M. M., & Marconato, J. C. (2006). Polímeros biodegradáveis: uma solução parcial para reduzir resíduos plásticos. *Química Nova*, 29(4), 811–816.
- Gebhardt, A. (2012). *Additive manufacturing: 3D printing for prototyping and manufacturing*. Munich: Hanser.
- Gibson, I., Rosen, D., & Stucker, B. (2015). *Additive manufacturing technologies* (2nd ed.). New York: Springer.
- Gomes Júnior, D. C., et al. (2016). Experimental acrylonitrile butadiene styrene and polyamide evisceration implant: a rabbit clinical and histopathology study. *Arquivo Brasileiro de Medicina Veterinária e Zootecnia*, 68(5), 1168–1176.



- Lima, M. V. A. (2009). Modelo de fatiamento adaptativo para prototipagem rápida (Dissertação de mestrado). Universidade Tecnológica Federal do Paraná.
- Matozinhos, I. P., et al. (2017). Impressão 3D: inovações no campo da medicina. *Revista Interdisciplinar Ciências Médicas*, 1(1), 143–162.
- Murphy, S. V., & Atala, A. (2014). 3D bioprinting of tissues and organs. *Nature Biotechnology*, 32(8), 773–785.
- Osorio, F. E., et al. (2018). Desenvolvimento de dispositivos ortopédicos por manufatura aditiva para animais de companhia. *Investigação*, 17(14), 19.
- Raulino, B. R. (2011). Manufatura aditiva: desenvolvimento de uma máquina baseada em FDM (Trabalho de graduação). Universidade de Brasília.
- Rengier, F., et al. (2010). 3D printing based on imaging data: review of medical applications. *International Journal of Computer Assisted Radiology and Surgery*, 5, 335–341.
- Salcher, A., et al. (2013). Utilização de ABS reciclado no processo FDM. In Congresso Brasileiro de Engenharia de Fabricação.
- Santos, M. A. R., et al. (2018). Estudo de caso: utilização de biomodelo no planejamento de órtese. In Congresso Brasileiro de Engenharia e Ciência dos Materiais.
- Sehlinger, A., et al. (2015). Potentially biocompatible polyacrylamides. *European Polymer Journal*, 65, 313–324.
- Silva, A. M., et al. (2003). Matriz óssea homóloga desmineralizada. *Ciência Rural*, 33, 539–545.
- Silva, G. C., & Kaminski, P. C. (2008). Prototipagem rápida aplicada (Dissertação). USP.
- Ventola, C. L. (2014). Medical applications for 3D printing. *Pharmacy and Therapeutics*, 39(10), 704–711.
- Volpato, N., & Carvalho, J. (2007). Prototipagem rápida como processo de fabricação. São Paulo: Edgard Blucher.
- Mohammed, S. I., et al. (2011). Mammography and ultrasound imaging of spontaneous canine mammary cancer and their similarities to human breast cancer. *Cancer Prevention Research*, 4(11), 1790–1798.
- Muramoto, C., et al. (2011). Avaliação ultrassonográfica de linfonodos na pesquisa de metástase de neoplasia mamária em cadelas. *Pesquisa Veterinária Brasileira*, 31(11), 1006–1013.
- Nosalova, N., et al. (2024). Canine mammary tumors: classification, biomarkers, and therapeutic perspectives. *International Journal of Molecular Sciences*, 25(5), 2891.
- Nyman, H. T., & O'Brien, R. T. (2007). The sonographic evaluation of lymph nodes. *Clinical Techniques in Small Animal Practice*, 22, 128–137.



- Peña, L., et al. (2021). Prognostic factors in canine mammary tumors. *Veterinary Oncology*.
- Perez Alenza, M. D., et al. (2021). Metabolic and hormonal influences on canine mammary cancer. *Journal of Small Animal Practice*.
- Queiroga, F., & Lopes, C. (2002). Canine mammary tumours: research on new prognostic factors. *Revista Portuguesa de Ciências Veterinárias*, 97, 119–127.
- Ribas, C. R., et al. (2012). Alterações clínicas relevantes em cadelas com neoplasias mamárias estadiadas. *Archives of Veterinary Science*, 17, 60–68.
- Sorenmo, K. U. (2003). Canine mammary gland tumors. *Veterinary Clinics of North America: Small Animal Practice*, 33, 573–596.
- Sorenmo, K. U., Rasotto, R., & Goldschmidt, M. H. (2011). Development, anatomy, histology, lymphatic drainage, clinical features and cell differentiation markers of canine mammary gland neoplasm. *Veterinary Pathology*, 48, 85–97.
- Sorenmo, K. U., et al. (2020). Prognostic staging and advanced imaging in canine mammary tumors. *Veterinary Oncology Reviews*.
- Swarte, M., et al. (2011). Comparison of sonographic features of benign and neoplastic deep lymph nodes in dogs. *Veterinary Radiology & Ultrasound*, 52(4), 451–456.
- Torabi, M., Aquino, S. L., & Harisinghani, M. G. (2004). Current concepts in lymph node imaging. *Journal of Nuclear Medicine*, 45, 1509–1518.
- Vázquez, P., et al. (2023). Epidemiology and clinical behavior of canine mammary tumors. *Veterinary Cancer Journal*.

