ReGeo ISSN: 2177-3246

UNILATERAL DUPLICATION OF THE FACIAL ARTERY: ANATOMICAL DESCRIPTION AND CLINICAL IMPLICATIONS

DUPLICAÇÃO UNILATERAL DA ARTÉRIA FACIAL: DESCRIÇÃO ANATÔMICA E IMPLICAÇÕES CLÍNICAS

DUPLICACIÓN UNILATERAL DE LA ARTERIA FACIAL: DESCRIPCIÓN ANATÓMICA E IMPLICACIONES CLÍNICAS

https://doi.org/10.56238/revgeov17n9-069

Data de submissão: 14/08/2026 **Data de publicação:** 14/09/2026

Helder Pimenta[1], Lara Cristina Braga Araujo[2], Artur Nogueira Maciel[3], Luizze Elizabeth de Souza Silveira[4], João Pedro Pinheiro Zuidgeest Vásquez[5], Raylan Lucas Carvalho de Aguiar[6], Radyr Gomes de Oliveira Neto[7], Thaís Vasconcelos de Vasconcelos[8], Livia Chacon Hildebrando da Silva[9], Caio Albyeri Carneiro de Oliveira[10], Henrique Vasconcelos[11], Clifferson dos Santos[12], Camilla Castro Gomes[13], Havilla Thaysa Ferreira da Silva Macedo[14], Camila Nepomuceno[15], Vanessa da Silva[16]

ABSTRACT

The facial artery is the principal source of vascular supply to the anterior face and is well known for its considerable anatomical variability. True duplication of the facial artery as opposed to a double origin from a linguofacial or thyrolinguofacial trunk is an uncommon finding with direct implications for head and neck surgery, free flap planning, and aesthetic injection procedures. We report a case identified during conventional dissection of a fresh-frozen cadaveric head at Instituto CTA (Manaus, Brazil), in which the right facial artery arose as a single trunk from the external carotid artery and underwent an early bifid division near the base of the mandible, giving rise to two parallel branches coursing in the same fascial plane, of visibly unequal caliber. No other vascular variations were identified in the same specimen. This pattern is discussed in light of the recently proposed Landfald Classification of facial artery variants and compared with previously reported cases of facial artery duplication. Awareness of this variant is relevant to preoperative vascular mapping and to

[1] Institution: Universidade do Estado do Amazonas. E-mail: hbinda@uea.edu.br
[2] Institution: Universidade do Estado do Amazonas.
[3] Institution: Universidade do Estado do Amazonas.
[4] Institution: Universidade do Estado do Amazonas.
[5] Institution: Universidade do Estado do Amazonas.
[6] Institution: Universidade do Estado do Amazonas.
[7] Institution: Universidade do Estado do Amazonas.
[8] Institution: Universidade do Estado do Amazonas.
[9] Institution: Universidade do Estado do Amazonas.
[10] Institution: Universidade do Estado do Amazonas.
[11] Institution: Universidade do Estado do Amazonas.
[12] Institution: Universidade do Estado do Amazonas.
[13] Institution: Faculdade Metropolitana de Manaus (FAMETRO).
[14] Institution: Faculdade Metropolitana de Manaus (FAMETRO).
[15] Institution: Universidade Nilton Lins.
[16] Institution: Universidade Luterana do Brasil (ULBRA).

minimizing the risk of ischemic and hemorrhagic complications in facial surgical and cosmetic procedures.

Keywords: Facial Artery. Anatomical Variation. Duplication. Cadaveric Dissection. Head and Neck Anatomy.

RESUMO
A artéria facial é a principal fonte de suprimento vascular para a face anterior e é bem conhecida por sua considerável variabilidade anatômica. A verdadeira duplicação da artéria facial, em contraste com uma origem dupla de um tronco linguofacial ou tirolinguofacial, é um achado incomum com implicações diretas para cirurgia de cabeça e pescoço, planejamento de retalhos livres e procedimentos de injeção estética. Relatamos um caso identificado durante dissecção convencional de uma cabeça cadavérica fresca e congelada no Instituto CTA (Manaus, Brasil), em que a artéria facial direita originou-se como um tronco único da artéria carótida externa e sofreu uma divisão bífida precoce perto da base da mandíbula, originando dois ramos paralelos percorrendo o mesmo plano fascial, com calibre visivelmente desigual. Nenhuma outra variação vascular foi identificada no mesmo espécime. Este padrão é discutido à luz da Classificação de Landfald recentemente proposta para variantes de artéria facial e comparado com casos previamente reportados de duplicação da artéria facial. O conhecimento desta variante é relevante para mapeamento vascular pré-operatório e para minimizar o risco de complicações isquêmicas e hemorrágicas em procedimentos cirúrgicos e cosméticos faciais.

Palavras-chave: Artéria Facial. Variação Anatômica. Duplicação. Dissecção Cadavérica. Anatomia de Cabeça e Pescoço.

RESUMEN
La arteria facial es la principal fuente de suministro vascular para la cara anterior y es bien conocida por su considerable variabilidad anatómica. La verdadera duplicación de la arteria facial, a diferencia de un origen dual de un tronco linguofacial o tirolinguofacial, es un hallazgo infrecuente con implicaciones directas para la cirugía de cabeza y cuello, la planificación de colgajos libres y los procedimientos de inyección estética. Reportamos un caso identificado durante la disección convencional de una cabeza cadavérica fresca y congelada en el Instituto CTA (Manaos, Brasil), en el cual la arteria facial derecha se originó como un tronco único de la arteria carótida externa y experimentó una división bífida temprana cerca de la base de la mandíbula, dando origen a dos ramas paralelas que cursan en el mismo plano fascial, con calibre visiblemente desigual. Ninguna otra variación vascular fue identificada en el mismo espécimen. Este patrón se discute a la luz de la Clasificación de Landfald recientemente propuesta para variantes de arteria facial y se compara con casos previamente reportados de duplicación de la arteria facial. El conocimiento de esta variante es relevante para el mapeo vascular preoperatorio y para minimizar el riesgo de complicaciones isquémicas y hemorrágicas en procedimientos quirúrgicos y cosméticos faciales.

Palabras clave: Arteria Facial. Variación Anatómica. Duplicación. Disección Cadavérica. Anatomía de Cabeza y Cuello.

1 INTRODUCTION

The facial artery (FA) is a major source of arterial supply to the superficial structures of the face. It typically arises from the anterior aspect of the external carotid artery near the greater horn of the hyoid bone, courses deep to the submandibular gland, crosses the inferior border of the mandible immediately anterior to the masseter muscle, and follows a tortuous ascending path toward the oral commissure, nose, and medial canthus.

Considerable variability has been documented in the origin, course, branching pattern, and termination of the FA. Reported variations include its origin from a common linguofacial or thyrolinguofacial trunk, high or aberrant origin, hypoplasia, premature termination, and, more rarely, duplication or bifid arterial configurations. In a computed tomography angiography study, Herrera-Núñez *et al.* (2020) identified a linguofacial trunk in 14.5% of the examined vessels, highlighting the importance of recognizing FA variations during radiological assessment and preoperative planning.

More recently, the Landfald Classification organized FA anatomy into five major types and fourteen subtypes according to arterial origin, branching configuration, termination, and potential surgical and radiological relevance (Landfald *et al.*, 2025). This classification provides a useful framework for describing uncommon arterial patterns and emphasizes that complex or duplicated configurations may require individualized assessment before reconstructive, maxillofacial, or aesthetic procedures.

Duplicated or bifid configurations of the FA have rarely been documented. Yoon *et al.* (2024) described a unilateral double FA in which two arteries supplied different regions of the face, illustrating the potential for separate vascular channels to replace the territory ordinarily supplied by a single vessel. Nevertheless, terminology remains inconsistent across the literature, and configurations described as “double,” “duplex,” “duplicated,” or “bifid” may represent anatomically distinct patterns. A clear description of the vessels’ origin, point of division, course, supplied territories, and relationship to adjacent structures is therefore essential.

The present report describes an unusual bifid configuration of the FA identified during routine cadaveric dissection. A single arterial trunk crossed the inferior border of the mandible and subsequently divided into two distinct ascending channels near the mandibular base. The objectives of this report are to document the anatomical configuration, assess its relationship to previously described duplicated and bifid patterns, and discuss its potential

implications for surgical, reconstructive, and minimally invasive aesthetic procedures involving the perimandibular and facial regions.

2 CASE REPORT

During routine anatomical dissection of a fresh-frozen head from a 68-year-old male cadaver at the Instituto CTA, Manaus, Amazonas, Brazil, an unusual arterial configuration was identified in the right hemiface. The underlying cause of death was unavailable; cardiorespiratory arrest was recorded as the terminal event. Dissection was performed using a standard layer-by-layer technique, with careful reflection of the skin and subcutaneous tissues to expose and preserve the vascular structures of the cervical, perimandibular, and facial regions.

The right facial artery arose as a single trunk from the external carotid artery and followed its expected cervical course toward the inferior border of the mandible. Near the mandibular border, where the vessel normally curves around the inferior margin of the mandibular body to enter the face, it divided into two distinct ascending arterial branches. The point of division was located 45.0 mm distal to the origin of the facial artery from the external carotid artery. Measurements were obtained using a Digimess digital caliper (Digimess, São Paulo, Brazil) with a resolution of 0.01 mm. Thus, the observed configuration resulted from an early bifurcation of a single facial artery rather than from two arteries with independent origins.

For descriptive purposes, the two divisions were designated the main branch (Branch A) and the accessory branch (Branch B). Branch A followed the conventional ascending course of the facial artery across the face. Branch B ascended along the anterior border of the masseter muscle and terminated at the inferior margin of the right orbicularis oculi muscle. Both branches coursed within the same fascial plane, and neither demonstrated a consistently superficial or deep position relative to the other. The two branches were visibly asymmetric in external caliber, with Branch B appearing substantially narrower than Branch A. However, because their external and luminal diameters were not formally measured, no conclusions regarding relative blood flow or functional dominance could be established.

Examination of the left hemiface revealed a facial artery with a conventional origin and course, confirming the unilateral nature of the variation. No common linguofacial or thyrolinguofacial trunk was identified. The lingual and superior thyroid arteries arose independently from the external carotid artery, and no additional arterial variations were

observed in the dissected region. The finding was therefore characterized as an isolated unilateral bifid configuration of the right facial artery. **Ethics Declaration**

This study was approved by the Research Ethics Committee of the Universidade do Estado do Amazonas (UEA), Brazil, under the Certificate of Presentation for Ethical Consideration (CAAE) No. 83194024.9.0000.5016. All procedures involving human anatomical specimens were conducted in accordance with the applicable ethical and institutional guidelines.

Figure 1

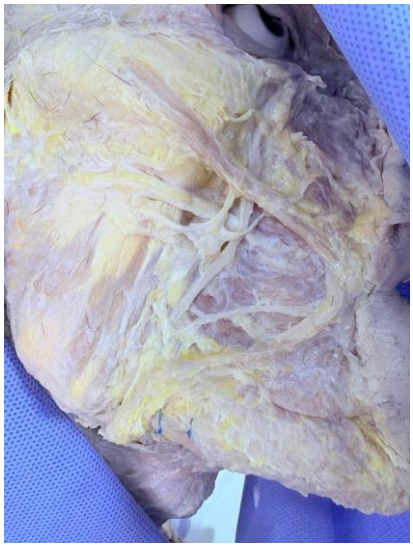

Source: Prepared by the authors.

Figure 2

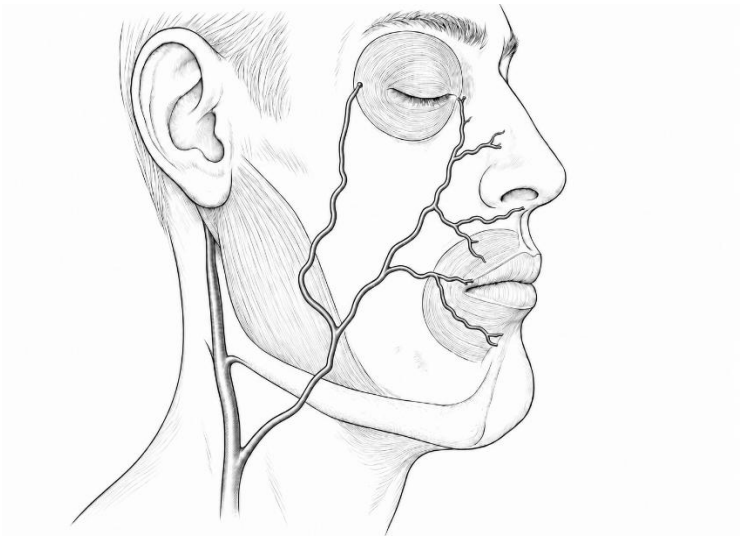

Source: Prepared by the authors.

3 DISCUSSION

The present case demonstrates an unusual unilateral bifid configuration of the facial artery in which a single vessel arising from the external carotid artery divided into two ascending branches 45.0 mm distal to its origin. This arrangement differs from a true double-origin facial artery because both branches arose from a common proximal trunk. Branch A constituted the main facial artery, followed its conventional course, and gave rise to the inferior labial, superior labial, lateral nasal, and angular arteries. In contrast, the narrower Branch B formed an accessory ascending channel that coursed along the anterior border of the masseter muscle and terminated at the inferior margin of the right orbicularis oculi muscle. The conventional arterial configuration observed in the left hemiface confirmed the unilateral nature of the finding.

The present pattern differs anatomically from the unilateral double facial artery reported by Yoon *et al.* (2024). In their case, two separate arteries arose from the external carotid system on either side of the origin of the maxillary artery and supplied different facial territories. The inferior vessel predominantly supplied the lower face, whereas the superior vessel supplied the upper face through the superior labial, lateral nasal, and angular arteries. In the present case, however, a single facial artery underwent an early bifurcation near the mandibular region. Moreover, Branch A retained the conventional branching pattern of the facial artery, whereas Branch B constituted an additional ascending arterial channel. Accordingly, the terms bifid facial artery or early bifurcation of the facial artery are more anatomically appropriate than true duplication.

The configuration observed in this specimen shows some similarity to previously described duplex branching patterns. Nguyen *et al.* (2024), in a study of 102 facial arteries from 52 formalin-fixed Vietnamese cadavers, identified a duplex pattern in 18 specimens (17.65%). In their series, a prominent lateral angular branch followed the nasojugal groove along the inferior border of the orbicularis oculi muscle. In the present case, Branch B also reached the inferior margin of the orbicularis oculi muscle; however, it separated from the main facial artery near the mandibular border and ascended along the anterior border of the masseter muscle. Meanwhile, Branch A maintained the conventional facial artery distribution and gave rise to the inferior and superior labial, lateral nasal, and angular arteries. These characteristics support interpretation of the finding as an early bifurcation producing an accessory ascending arterial channel rather than two independent or codominant facial arteries.

Variations in the origin of the facial artery are more frequently documented than bifid or double-artery configurations. Herrera-Núñez *et al.* (2020), using computed tomography angiography, identified a linguofacial trunk in 14.5% of the examined vessels. In the present specimen, the facial, lingual, and superior thyroid arteries arose independently from the external carotid artery. Therefore, the observed variation involved the division and facial course of the facial artery rather than its origin. This distinction is clinically relevant because variations in origin primarily affect cervical surgical approaches, whereas an early division near the mandibular border may have more direct implications for procedures involving the lower and middle facial regions.

Within the framework of the Landfald Classification, the present configuration departs from the classical pattern because a single proximal facial artery gives rise to an additional ascending channel (Landfald *et al.*, 2025). It may broadly correspond to an aberrant or accessory facial artery pattern. Nevertheless, assignment to a specific subtype should be approached cautiously because this classification considers multiple characteristics, including arterial origin, branching pattern, termination, supplied territory, and radiological detectability. The present finding also demonstrates the importance of describing vascular variations according to their origin or point of division, course, caliber, branches, termination, and relationships with adjacent structures rather than relying exclusively on terms such as double, duplex, or duplicated.

The embryological basis of this variation remains uncertain. The arteries of the face develop through remodeling and selective persistence or regression of vascular channels associated with the external carotid system. An early division of a single facial artery may reflect persistence of an accessory vascular channel during this remodeling process. However, because no embryological, angiographic, or histological evidence was available, this explanation remains hypothetical and should not be regarded as a definitive developmental mechanism.

The finding may be clinically relevant during reconstructive, maxillofacial, oncologic, and aesthetic procedures. The facial artery serves as an important vascular pedicle and surgical landmark in facial artery musculomucosal, nasolabial, and cervicofacial flaps. An unrecognized early bifurcation could expose the accessory branch to inadvertent injury or ligation during dissection near the mandibular border or anterior margin of the masseter. Although Branch A retained the conventional branches of the facial artery, the contribution of

Branch B to the perfusion of the infraorbital region could not be determined. Consequently, the clinical effect of injury to this accessory channel remains uncertain.

The accessory branch may also be relevant to minimally invasive facial procedures. Its course from the perimandibular region toward the inferior margin of the orbicularis oculi muscle represents an additional arterial pathway that could be encountered during filler injection, facial contouring, or other percutaneous interventions. Nevertheless, the present anatomical observation does not establish the frequency, depth variability, or risk associated with this configuration in living individuals. When detailed vascular characterization is clinically warranted, Doppler ultrasonography, computed tomography angiography, or magnetic resonance angiography may assist in identifying atypical facial arterial courses.

The difference in caliber between the two branches is also noteworthy. Branch B was visibly narrower than Branch A and could therefore be mistaken for a minor collateral vessel during surgical dissection. Its extended course from the mandibular region to the inferior margin of the orbicularis oculi muscle, however, distinguishes it from a short local branch. Because the external and luminal diameters were not formally measured and the vessels were not injected with contrast or colored material, neither the hemodynamic contribution nor the precise perfusion territory of Branch B could be established. The difference in caliber should therefore be interpreted as a qualitative morphological observation rather than as evidence of functional dominance or unequal blood flow.

The use of a fresh-frozen specimen facilitated dissection of the vascular structures while preserving their relationships with the surrounding tissues. However, no conclusions regarding the native arterial caliber can be drawn because the vessels were not examined under physiological intravascular pressure. Although the preservation method would not be expected to produce the observed branching configuration, it may have influenced the apparent caliber and physical characteristics of the arterial walls.

This report is limited by its single-specimen design, the absence of formal measurements of the external and luminal diameters of the two branches, and the lack of vascular injection, angiographic assessment, and histological examination. These limitations prevented confirmation of vessel patency, anastomotic connections, wall structure, hemodynamic relevance, and precise perfusion territories. Nevertheless, contralateral dissection confirmed the unilateral nature of the variation, and direct anatomical examination documented the origin, point of division, course, branching pattern, relative caliber, and termination of both arterial channels. This case expands the anatomical documentation of

bifid facial artery configurations and underscores the need to consider accessory arterial channels even after the main facial artery has been identified at its expected location near the mandibular border.

4 CONCLUSION

This report describes an unusual unilateral early bifurcation of the right facial artery, occurring 45.0 mm distal to its origin from the external carotid artery. The resulting bifid configuration consisted of a main branch that followed the conventional facial artery course and gave rise to the inferior labial, superior labial, lateral nasal, and angular arteries, and a narrower accessory branch that ascended along the anterior border of the masseter muscle and terminated at the inferior margin of the orbicularis oculi muscle. This pattern differs from previously reported double facial arteries with independent origins and is more appropriately characterized as a bifid facial artery with an accessory ascending branch. Recognition of this configuration may be relevant during facial surgery, flap elevation, and minimally invasive aesthetic procedures. The finding underscores the importance of careful perimandibular dissection and individualized vascular assessment when detailed knowledge of the facial arterial anatomy is clinically required.

DECLARATIONS

Ethics approval: Not applicable.

REFERENCES

Figure 1. Dissection of the perimandibular region of the right hemiface in a fresh-frozen cadaveric specimen, showing an early bifurcation of the facial artery into two branches of unequal caliber that ascend in parallel within the same fascial plane.

Figure 2. Schematic illustration of the right hemiface depicting the early bifurcation of the facial artery and the parallel ascending courses of its two branches, including their principal facial tributaries.

Herrera-Núñez M, Menchaca-Gutiérrez JL, Pinales-Razo R, Elizondo-Riojas G, Quiroga-Garza A, Fernandez-Rodarte BA, Elizondo-Omaña RE, Guzmán-López S (2020) Origin variations of the superior thyroid, lingual, and facial arteries: a computed tomography angiography study. Surg Radiol Anat 42:1085–1093. https://doi.org/10.1007/s00276-020-02507-6

Koziej M, Bonczar M, Ostrowski P, Piątek-Koziej K, Bonczar T, Pasternak A, Dziedzic M, Walocha J (2022) Termination points of the facial artery—a meta-analysis. Clin Anat 35:469–476. https://doi.org/10.1002/ca.23817

Landfald IC, Adamek J, Siva Kumar YAP, Olewnik Ł, Coleman J, Labetowicz P (2026) Anatomy reimagined: the Landfald classification as a transformative surgical and radiological guide to facial artery variants. Ann Anat 263:152712. https://doi.org/10.1016/j.aanat.2025.152712

Nguyen VH, Lin CK, Nguyen TA, Cai THNT (2024) The branching patterns and termination points of the facial artery: a cadaveric anatomical study. Arch Craniofac Surg 25:77–84. https://doi.org/10.7181/acfs.2024.00038

Yoon CY, Engler AM, Konisky H, Hogeg A, Detton AJ, Erlich MA, Mishall PL, Pinkas A (2024) Unilateral double facial artery: an anatomic variant and clinical implications. Case Rep Plast Surg Hand Surg 11:2376136. https://doi.org/10.1080/23320885.2024.2376136