ReGeo ISSN: 2177-3246

LUMBOSACRAL MIDLINE APLASIA CUTIS CONGENITA WITHOUT SPINAL DYSRAPHISM ON MAGNETIC RESONANCE IMAGING: A CASE REPORT

APLASIA CUTIS CONGÊNITA NA LINHA MÉDIA LOMBOSSACRA SEM DISPLASIA RAQUIDIANA EM RESSONÂNCIA MAGNÉTICA: UM RELATO DE CASO

APLASIA CUTIS CONGÉNITA EN LA LÍNEA MEDIA LUMBOSACRA SIN DISPLASIA RAQUÍDEA EN RESONANCIA MAGNÉTICA: UN REPORTE DE CASO

https://doi.org/10.56238/revgeov17n11-060

Data de submissão: 13/10/2026 **Data de publicação:** 13/11/2026

Edson Koji Suzuki[1], Feres Abrão[2], Osmi Hamamoto[3], Leonardo Furukawa Suzuki[4], Rodolfo Oliveira Medeiros[5], Laila Abrão[6], Camila Abrão Costa Buzeto[7], Marines Laveso de Brito[8], Gustavo Henrique de Paulo Ribeiro Ponciano[9], Thabatha Aline Trevisan[10], Isis Carrero Zequini de Freitas[11]

ABSTRACT

Introduction: Aplasia cutis congenita is a focal absence of skin at birth and involves the scalp in the vast majority of cases. When located on the lumbosacral midline, it is regarded as a high-risk cutaneous marker of occult spinal dysraphism, which warrants investigation of the neuraxis. Case report: A male late preterm newborn (35 weeks and 1 day), large for gestational age, was born to a mother with type 1 diabetes mellitus, chronic hypertension, obesity and preeclampsia. On neonatal examination, he had an erosive lesion with a membranous appearance on the lumbosacral midline, without discharge, and preserved posture, tone, strength and primitive reflexes. The neonatal team raised the hypothesis of closed lumbosacral dysraphism, and the lesion was managed with a silicone foam dressing following neurosurgical advice. Lumbosacral radiography at 23 days of life showed no abnormalities. Contrast-enhanced magnetic resonance imaging performed under sedation at 8 months showed a conus medullaris of normal morphology, position and signal, a spinal canal of preserved caliber and no pathological enhancement. Neonatal screening and cardiac, ophthalmological and hearing assessments revealed no relevant associated anomalies, and growth remained adequate. Discussion: Lumbosacral aplasia cutis should be

[1] Physician specialized in Pediatrics. Institution: Faculdade de Medicina de Marília (FAMEMA).
[2] PhD in Gynecology. Institution: Universidade de Marília (UNIMAR).
[3] Physician specialized in Neurosurgery. Institution: Faculdade de Medicina de Marília (FAMEMA).
[4] Physician. Institution: Faculdade de Medicina de Marília (FAMEMA).
[5] PhD in Education. Institution: Universidade de Marília (UNIMAR).
[6] Master in Structural and Functional Interactions in Rehabilitation. Institution: Universidade de Marília (UNIMAR).
[7] Physician specialized in Gynecology and Obstetrics. Institution: Faculdade de Medicina de Marília (FAMEMA).
[8] Physician specialized in Gynecology and Obstetrics. Institution: Universidade de Marília (UNIMAR).
[9] Physician specialized in Gynecology and Obstetrics, with specialized practice in Human Reproduction and Couple Infertility. Institution: Universidade de Marília (UNIMAR).
[10] Medical student. Institution: Universidade de Marília (UNIMAR).
[11] Physician specialized in Gynecology and Obstetrics. Institution: Faculdade de Medicina de Marília (FAMEMA).

managed as a high-risk marker, especially when maternal factors increase the likelihood of neural tube defects, but it may occur without an underlying spinal malformation. Conclusion: Clinical and radiological correlation made it possible to rule out structural dysraphism, although follow-up of neurological, urological and orthopedic development remains necessary.

Keywords: Aplasia Cutis Congenita. Spinal Dysraphism. Spina Bifida Occulta. Skin Abnormalities. Magnetic Resonance Imaging. Case Reports.

RESUMO

Introdução: Aplasia cutânea congênita é uma ausência focal de pele ao nascimento e envolve o couro cabeludo na grande maioria dos casos. Quando localizada na linha média lombossacra, é considerada um marcador cutâneo de alto risco de disrafismo espinal oculto, que justifica a investigação do neuroeixo. Relato de caso: Um recém-nascido prematuro tardio do sexo masculino (35 semanas e 1 dia), grande para a idade gestacional, nasceu de mãe com diabetes mellitus tipo 1, hipertensão crônica, obesidade e pré-eclampsia. No exame neonatal, apresentava uma lesão erosiva com aparência membranosa na linha média lombossacra, sem descarga, e postura, tônus, força e reflexos primitivos preservados. A equipe neonatal levantou a hipótese de disrafismo lombossacro fechado, e a lesão foi manejada com curativo de espuma de silicone seguindo orientação neurocirúrgica. Radiografia lombossacra aos 23 dias de vida não mostrou anormalidades. Ressonância magnética com realce de contraste realizada sob sedação aos 8 meses revelou um cone medular de morfologia, posição e sinal normais, um canal espinal de calibre preservado e nenhum realce patológico. Triagem neonatal e avaliações cardíaca, oftalmológica e auditiva não revelaram anomalias associadas relevantes, e o crescimento permaneceu adequado. Discussão: Aplasia cutânea lombossacra deve ser manejada como um marcador de alto risco, especialmente quando fatores maternos aumentam a probabilidade de defeitos do tubo neural, mas pode ocorrer sem uma malformação espinal subjacente. Conclusão: A correlação clínica e radiológica possibilitou descartar disrafismo estrutural, embora o acompanhamento do desenvolvimento neurológico, urológico e ortopédico permaneça necessário.

Palavras-chave: Aplasia Cutânea Congênita. Disrafismo Espinal. Espinha Bífida Oculta. Anomalias de Pele. Ressonância Magnética. Relatos de Casos.

RESUMEN

Introducción: Aplasia cutis congénita es una ausencia focal de piel al nacer e involucra el cuero cabelludo en la gran mayoría de los casos. Cuando se localiza en la línea media lumbosacra, se considera un marcador cutáneo de alto riesgo de disrafismo espinal oculto, lo que justifica la investigación del neuroeje. Reporte de caso: Un recién nacido prematuro tardío de sexo masculino (35 semanas y 1 día), grande para la edad gestacional, nació de madre con diabetes mellitus tipo 1, hipertensión crónica, obesidad y preeclampsia. En el examen neonatal, presentaba una lesión erosiva con apariencia membranosa en la línea media lumbosacra, sin drenaje, y postura, tono, fuerza y reflejos primitivos preservados. El equipo neonatal planteó la hipótesis de disrafismo lumbosacro cerrado, y la lesión fue manejada con apósito de espuma de silicona siguiendo orientación neuroquirúrgica. Radiografía lumbosacra a los 23 días de vida no mostró anormalidades. Resonancia magnética con contraste realizada bajo sedación a los 8 meses reveló un cono medular de morfología, posición y señal normales, un canal espinal de calibre preservado y sin realce patológico. El cribado neonatal y las evaluaciones cardiológica, oftalmológica y auditiva no

revelaron anomalías asociadas relevantes, y el crecimiento se mantuvo adecuado. Discusión: Aplasia cutis lumbosacra debe ser manejada como un marcador de alto riesgo, especialmente cuando factores maternos aumentan la probabilidad de defectos del tubo neural, pero puede ocurrir sin una malformación espinal subyacente. Conclusión: La correlación clínica y radiológica permitió descartar disrafismo estructural, aunque el seguimiento del desarrollo neurológico, urológico y ortopédico sigue siendo necesario.

Palabras clave: Aplasia Cutis Congénita. Disrafismo Espinal. Espina Bífida Oculta. Anomalías de Piel. Resonancia Magnética. Reportes de Casos.

1 INTRODUCTION

Aplasia cutis congenita (ACC) is characterized by the localized absence of epidermis, dermis and, in some cases, subcutaneous tissue at birth. The lesion may present as an erosion, an ulcer, a membranous area or an atrophic scar, depending on the depth of the defect and on whether healing has already taken place in utero (FRIEDEN, 1986; BRACKENRICH; SALEH; BROWN, 2025). Its incidence is estimated at 1 to 3 cases per 10,000 births (BRACKENRICH; SALEH; BROWN, 2025). In a European population-based study drawing on congenital anomaly registries, prevalence was 5.1 per 100,000 births, the scalp was involved in 96.4% of cases and associated anomalies were present in about one third of them (COI *et al*., 2023). Extracranial forms are therefore uncommon and have been described mainly in isolated reports (EL MOULOUA *et al*., 2024).

The Frieden classification, proposed in 1986 and still in use, groups ACC into nine categories according to lesion location and associated conditions. One of these categories comprises lesions overlying embryological malformations such as myelomeningocele and spinal dysraphism (FRIEDEN, 1986; BRACKENRICH; SALEH; BROWN, 2025). For this reason, ACC on the dorsal midline carries a clinical meaning distinct from that of isolated scalp lesions.

Occult spinal dysraphisms (OSD) are skin-covered anomalies of neural tube closure, including intraspinal lipomas, dermal sinus, thickened filum terminale and tethered cord. Because skin and neural tube both derive from the ectoderm and separate during neurulation, errors at this stage may leave cutaneous marks over the affected vertebral segment. In risk stratification proposals for lumbosacral markers, ACC and congenital scars over the lower spine are listed among high-risk findings, together with lipomas, caudal appendages, dermal sinuses and large hemangiomas (SEWELL; CHIU; DROLET, 2015). Between 50% and 80% of closed dysraphisms show a cutaneous marker visible from birth (HUNSAKER *et al*., 2023), and early recognition of these signs allows diagnosis before the onset of neurological, urological or orthopedic deficits, which may develop progressively during growth (VETRANO *et al*., 2022).

Imaging investigation of these infants, however, is not yet standardized. Ultrasonography is the initial examination in the first months of life, while the posterior vertebral elements are not fully ossified, and magnetic resonance imaging (MRI) is the reference method for anatomical characterization of the neuraxis, with the disadvantage of requiring sedation in most infants (HUNSAKER *et al*., 2023; KRISS; DESAI, 1998). In a series

of infants referred for lumbosacral cutaneous findings and screened by ultrasonography, about one quarter had abnormal results (SHIELDS *et al*., 2021), and an international survey of pediatric neurosurgeons found strong agreement on the indication for MRI in focal dysplastic skin on the lumbar midline, but wide disagreement for other markers (SVOKOS *et al*., 2021).

This report describes a case of lumbosacral midline ACC identified at birth in an infant of a mother with pregestational diabetes, in whom MRI showed no spinal dysraphism. The aim is to discuss the clinical and radiological correlation and the diagnostic pathway in the presence of a high-risk cutaneous marker. The report follows the CARE guidelines for case reports (RILEY *et al*., 2017).

2 CASE REPORT

2.1 MATERNAL HISTORY AND BIRTH

The patient was a male newborn whose 30-year-old mother had obesity, chronic hypertension, type 1 diabetes mellitus managed with continuous subcutaneous insulin infusion and hypothyroidism treated with levothyroxine. The list of maternal medications recorded in the discharge summary included amlodipine, losartan and methyldopa (3 g/day) for blood pressure control, without specifying the periods of pregnancy during which each drug was used. Pregnancy was complicated by preeclampsia, and delivery was by cesarean section, indicated by the maternal comorbidities and by failure to progress, at a gestational age of 35 weeks and 1 day estimated by ultrasonography.

The newborn was in cephalic presentation, with amniotic fluid of normal volume, clear and with few flakes. He weighed 3,160 g, measured 49 cm and had a head circumference of 35 cm, being classified as large for gestational age by the INTERGROWTH-21st charts. Apgar scores were 8 and 9 at the first and fifth minutes. Because of early respiratory distress, he received positive pressure ventilation and continuous positive airway pressure for about 10 minutes, with a fraction of inspired oxygen of 21%, and was kept in an incubator without supplemental oxygen, with a diagnosis of transient tachypnea of the newborn (Silverman-Andersen score 3/4). He also had hypothermia (34.6 °C) and a heart murmur requiring investigation. Serial capillary glucose values were 99, 165, 73, 79, 89 and 73 mg/dL, with no episodes of hypoglycemia. His blood type was O positive, and the direct antiglobulin test was negative.

The respiratory pattern improved within the first hours, and the newborn was transferred to rooming-in. The mother required intensive care unit admission for metabolic stabilization in the immediate postpartum period, and the newborn was discharged on the fifth day of life, together with the mother, on breastfeeding with infant formula prescribed as needed.

2.2 LUMBOSACRAL SKIN LESION

Neonatal physical examination revealed an erosive lesion on the lumbosacral midline, covered by an intact membrane and without discharge. The records describe no other associated cutaneous stigmata, such as a hair tuft, caudal appendage, subcutaneous swelling suggestive of lipoma, dermal sinus opening or hemangioma, and the spine was described as free of deviations or deformities. Given the location, the neonatal team recorded closed lumbosacral dysraphism as the diagnostic hypothesis, and the lesion was covered with a silicone foam dressing (Mepilex®), as advised by neurosurgery. The attending pediatrician characterized the lesion as lumbosacral midline ACC.

On photographic documentation, the lesion is small, oval and well demarcated, with a smooth, shiny, membranous surface and a whitish-bluish center, with no signs of drainage or infection (Figure 1). Lesion dimensions were not recorded.

Figure 1

Congenital skin lesion on the lumbosacral midline, clinically characterized as aplasia cutis congenita. An oval, well-demarcated area with a membranous appearance, a whitish-bluish center and no discharge is observed



Source: archive of the attending team, with the authorization of the legal guardians.

2.3 NEUROLOGICAL AND PHYSICAL EXAMINATION

Neonatal examination documented preserved posture, tone and muscle strength, with primitive reflexes present. The skull was symmetrical, with a flat anterior fontanelle and apposed sutures, without caput succedaneum or cephalohematoma. The hips were symmetrical, with negative Ortolani and Barlow maneuvers; the genitalia were typically male, with descended testes and an orthotopic urethral meatus, without hypospadias or epispadias; and the limbs showed no deformities or rotational or angular deviations. Although reassuring, these findings were not considered sufficient to exclude OSD, which is usually asymptomatic in the first months of life, and anatomical investigation was pursued.

2.4 IMAGING INVESTIGATION

Lumbosacral spine radiography at 23 days of life showed a normal lumbar axis, anatomically normal vertebral bodies, preserved intervertebral spaces, intact laminae, pedicles, isthmi and processes, and no abnormalities of the sacrum or sacroiliac joints.

MRI of the lumbosacral spine was performed at 8 months and 25 days of life, under anesthesia, with multiplanar acquisitions before and after contrast administration. The report described vertebral bodies, pedicles and neural arch of preserved morphology and signal intensity; intervertebral discs in normal position and with usual signal; a conus medullaris of normal morphology, position and signal intensity; a spinal canal of normal caliber; patent neural foramina bilaterally; unremarkable muscle planes and paravertebral soft tissues; and no pathological enhancement after contrast. The report did not specify the vertebral level of the conus termination or the thickness of the filum terminale. Sagittal T2-weighted images illustrate the integrity of the spinal canal and neural structures along the lumbosacral spine (Figure 2).

Figure 2

Magnetic resonance imaging of the lumbosacral spine at 8 months of age, sagittal T2-weighted images near the midline (A and B). Vertebral bodies, intervertebral discs and spinal canal are preserved; the conus medullaris has normal morphology and signal, with no intraspinal lipoma, mass or abnormality of the posterior soft tissues. Identifying data have been removed

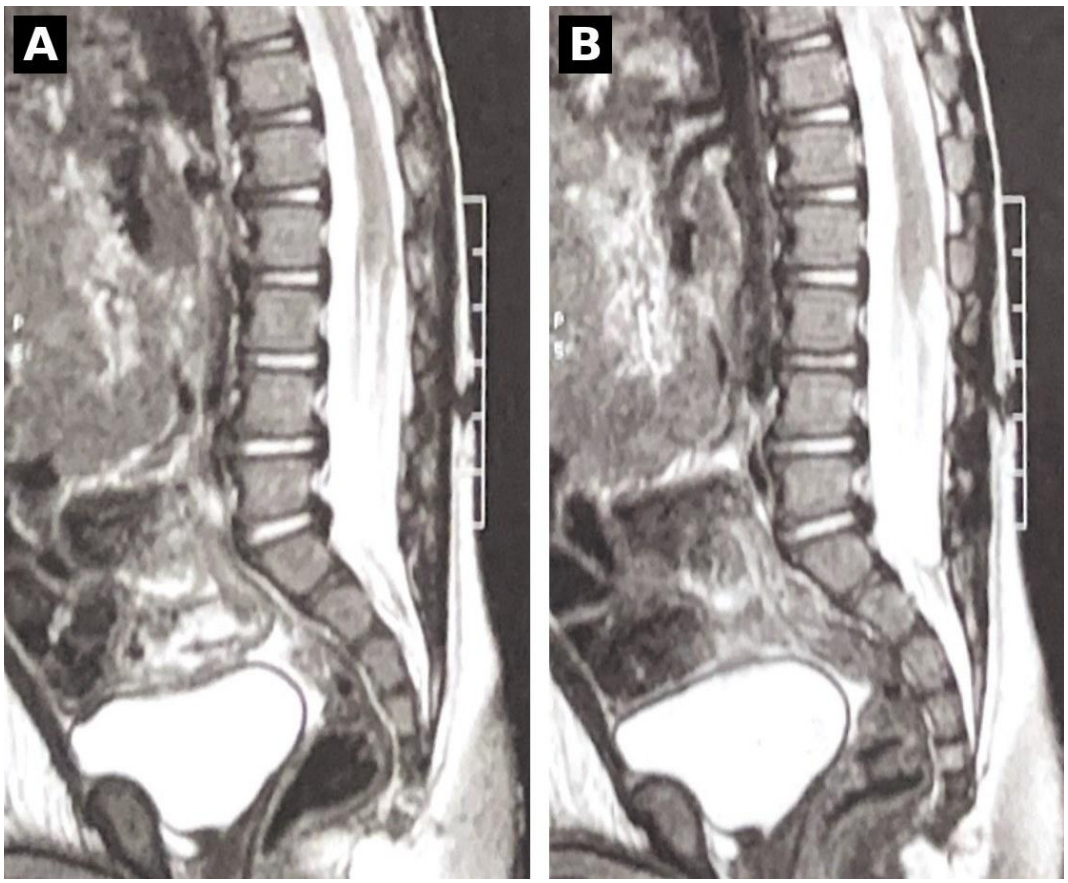

Source: archive of the attending team.

Axial images complement the sagittal assessment, showing the neural structures centered within the spinal canal and an intact posterior arch at the lumbar levels (Figure 3).

Figure 3

Magnetic resonance imaging of the lumbar spine, axial T2-weighted images (A) Upper lumbar segment, with neural structures centered within the spinal canal. (B) Lower lumbar segment, with cauda equina roots of usual distribution and an intact posterior vertebral arch. Identifying data have been removed.

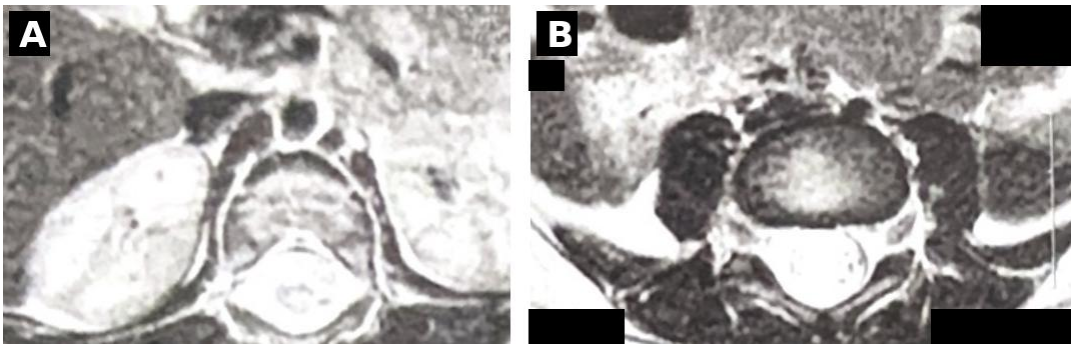

Source: archive of the attending team.

2.5 NEONATAL SCREENING AND ASSESSMENT OF OTHER SYSTEMS

Expanded newborn blood spot screening, collected on the fifth day of life, showed all parameters within normal limits: neonatal thyroid-stimulating hormone of 1.51 µIU/mL and neonatal thyroxine of 18.4 µg/dL; 17-hydroxyprogesterone of 7.56 ng/mL; immunoreactive trypsinogen of 14.93 ng/mL; normal biotinidase, galactose-1-phosphate uridyltransferase and glucose-6-phosphate dehydrogenase activities; normal total galactose; hemoglobin FA pattern; nonreactive toxoplasmosis IgM; and an amino acid and acylcarnitine profile by tandem mass spectrometry without abnormalities. The red reflex test was normal in the maternity ward and confirmed by an ophthalmologist at 17 days of life, and pre- and postductal pulse oximetry was 100%. Transient evoked and distortion product otoacoustic emissions, performed at 27 days, were present at all tested frequencies bilaterally.

To investigate the murmur, echocardiography and electrocardiography were performed at 23 days of life. The echocardiogram showed *situs solitus*, concordant atrioventricular and ventriculoarterial connections, mild flow across the interatrial septum consistent with patent foramen ovale and an ejection fraction of 73%, with no other structural abnormalities. The electrocardiogram revealed sinus rhythm, a heart rate of 147 bpm, infantile repolarization and the right ventricular predominance typical of the newborn, and was considered normal for age.

In the maternity ward, the tongue-tie test using the Bristol Tongue Assessment Tool scored 8, considered normal. At 19 days of life, speech-language assessment using the

Martinelli protocol recorded feeds at intervals of one hour or less, with fatigue, falling asleep and releasing the nipple during sucking, with formula supplementation, and an anatomofunctional score of 8 points, equal to or above the cutoff of 7 that suggests interference of the frenulum with tongue movements. The management adopted for this finding is not recorded in the documentation reviewed. World Health Organization growth charts showed weight, length and head circumference within the normal range throughout the first year of life.

2.6 MANAGEMENT AND FOLLOW-UP

No neurosurgical intervention was indicated. The lesion was managed conservatively with dressings, and the normal MRI allowed the infant to remain under outpatient pediatric follow-up. The available documentation does not describe the course of lesion healing, the attainment of motor milestones or urological assessment. The sequence of the main events and results is summarized in Chart 1.

Figure 1. Timeline of the investigation and main results.

AGE	EVENT OR EXAMINATION	MAIN FINDINGS
Birth (day 0)	Cesarean section at 35 weeks and 1 day	3,160 g, large for gestational age; Apgar 8/9; transient tachypnea, hypothermia and murmur requiring investigation
Day 0	Neonatal physical examination	Erosive lesion with intact membrane on the lumbosacral midline; posture, tone, strength and primitive reflexes preserved; hypothesis of closed lumbosacral dysraphism
Days 0 to 5	Neonatal hospital stay	Silicone foam dressing as advised by neurosurgery; glucose values without hypoglycemia
Day 5	Hospital discharge and blood spot screening	Expanded screening normal; red reflex and pulse oximetry normal; tongue-tie test (Bristol) 8
Day 17	Ophthalmological assessment	Normal red reflex bilaterally
Day 19	Speech-language assessment (Martinelli)	Anatomofunctional score of 8 points
Day 23	Lumbosacral spine radiography	No bone abnormalities
Day 23	Echocardiography and electrocardiography	Patent foramen ovale, ejection fraction of 73%; electrocardiogram normal for age
Day 27	Otoacoustic emissions	Present bilaterally
8 months and 25 days	Contrast-enhanced lumbosacral MRI under anesthesia	Normal conus medullaris, spinal canal and neural arch; no pathological enhancement; no structural dysraphism
First year	Growth monitoring (WHO charts)	Weight, length and head circumference within normal limits

Source: Prepared by the authors.

3 DISCUSSION

This case describes a congenital skin lesion on the lumbosacral midline, clinically interpreted as ACC, that prompted investigation of the neuraxis and in which MRI showed no spinal dysraphism. The contribution of this report lies not in the rarity of the presentation but in the diagnostic pathway: a high-risk cutaneous marker, in a maternal context that raises the likelihood of neural tube defects, investigated through to complete anatomical characterization.

Lumbosacral ACC must be distinguished from the broader group of lumbosacral cutaneous markers. The available data on diagnostic yield generally come from mixed populations dominated by sacral dimples, asymmetries and bifurcations of the gluteal cleft. In these series, the presence of two or more markers is associated with a higher probability of abnormal findings than a single marker (SHIELDS *et al*., 2021), and markers considered high risk, ACC among them, account for most of the dysraphisms identified (SEWELL; CHIU; DROLET, 2015; KRISS; DESAI, 1998). The literature specifically addressing lumbosacral ACC, by contrast, consists essentially of isolated reports, which precludes a precise estimate of the frequency of underlying dysraphism. Similar lesions have been described without an underlying neuroectodermal defect, including one with a hair collar sign (DHATTARWAL; YADAV, 2024), as has extensive truncal ACC without other anomalies managed conservatively (EL MOULOUA *et al*., 2024). The present case adds to these reports and reinforces that the association, although clinically relevant, is not obligatory.

From a classification standpoint, the lesion could be assigned to the Frieden group of ACC overlying embryological malformations only if an underlying malformation were present (FRIEDEN, 1986; BRACKENRICH; SALEH; BROWN, 2025). With a normal MRI, the presentation corresponds to apparently isolated extracranial ACC. The diagnosis, however, is clinical. The differential diagnosis includes dermal sinus, whose opening is usually pinpoint and connected to a deep tract; atrophic congenital scars; ulcerated infantile hemangioma; and birth trauma, a relevant consideration in a cesarean delivery. The membranous surface, the presence of the lesion from birth and the absence of discharge or an apparent tract favor ACC, although no specialist dermatological assessment or histopathological study was performed.

The maternal context adds interest to the case. Pregestational diabetes is a recognized risk factor for neural tube defects, with roughly twice the odds in a meta-analysis of risk factors (JIA *et al*., 2019). In European registry data, pregestational diabetes was strongly associated with caudal regression sequence and with multiple anomalies, although the increase in risk did not reach significance for spina bifida alone (GARNE *et al*., 2012). These findings raise the pretest probability of an abnormality of the lumbosacral segment and support the decision to investigate, without allowing a causal role to be attributed to the maternal disease in this patient's skin lesion.

The list of maternal medications also included losartan, an angiotensin II receptor antagonist. Use of this drug class during pregnancy, particularly from the second trimester

onward, is associated with a fetopathy characterized by oligohydramnios, renal failure, hypotension, pulmonary hypoplasia and hypocalvaria (BULLO *et al*., 2012). The records do not detail the period of exposure, but the newborn showed none of these findings: amniotic fluid volume was normal, the skull was normal on examination and the neonatal course was consistent with late prematurity and with an infant of a diabetic mother. ACC is not part of the spectrum described for this fetopathy, and there is no basis for relating the drug exposure to the lumbosacral lesion.

Regarding imaging, plain radiography performed in the first month assesses only the bony framework and does not exclude intradural abnormalities such as lipomas, a thickened filum or a low-lying conus. Ultrasonography is the preferred screening examination in the first months of life, while incomplete ossification of the posterior elements provides an acoustic window, and MRI is reserved for confirmation and surgical planning or indicated directly in the presence of high-risk markers (HUNSAKER *et al*., 2023; KRISS; DESAI, 1998; SEWELL; CHIU; DROLET, 2015). There is no record of spinal ultrasonography in this case, and MRI was performed at 8 months under anesthesia. This interval reflects the lack of uniform practice described in the literature, in which pediatric neurosurgeons largely agree on the indication for MRI in focal dysplastic skin on the lumbar midline but disagree on the method and timing of investigation (SVOKOS *et al*., 2021).

The normal MRI is the central finding of this report. The preserved morphology and position of the conus medullaris, the absence of lipoma, mass or abnormal enhancement and the integrity of the neural arch exclude the structural forms of OSD most often associated with cutaneous markers. Nevertheless, MRI reports should explicitly state the level of conus termination and the thickness of the filum terminale, which are decisive parameters in the evaluation of tethered cord. Moreover, anatomical normality does not replace clinical surveillance: because manifestations of OSD may emerge with growth, follow-up of gait, sphincter control and lower limb posture is recommended, with specialist reassessment if warning signs appear (VETRANO *et al*., 2022).

The remaining findings were interpreted as unrelated to the skin lesion. Patent foramen ovale is common in the first weeks of life and, in the setting of an otherwise normal echocardiogram, does not suggest a syndromic association. Expanded newborn screening and the hearing and ophthalmological assessments were normal, and no dysmorphic features were described, although these examinations are not equivalent to a genetic

investigation. The discrepancy between the tongue-tie test in the maternity ward and the protocol applied at 19 days is an incidental finding unrelated to the lumbosacral condition.

3.1 LIMITATIONS

This report is based on retrospective documentation. The diagnosis of ACC was clinical, without specialist dermatological assessment or histopathological confirmation, and the lesion dimensions were not recorded. There is no documentation of spinal ultrasonography in the neonatal period. The MRI report did not state the level of the conus medullaris or the thickness of the filum terminale. Data on lesion healing, motor milestones and urinary function are lacking, and the periods of exposure to maternal medications were not specified. Despite these limitations, the availability of photographic documentation, a detailed neonatal examination and contrast-enhanced MRI allows a consistent clinical and radiological correlation.

4 FINAL CONSIDERATIONS

Lumbosacral midline ACC should be treated as a high-risk cutaneous marker of occult spinal dysraphism and investigated by imaging, particularly when maternal factors increase the likelihood of neural tube defects. In this case, MRI showed no spinal malformation, which characterizes the lesion as apparently isolated. This experience highlights three practical points: plain radiography is not sufficient to rule out dysraphism; early ultrasonography, when available, may bring the investigation forward and avoid sedation; and MRI reports should state the level of the conus medullaris and the thickness of the filum terminale. Even with normal imaging, clinical follow-up of neurological, urological and orthopedic development remains indicated.

REFERENCES

BRACKENRICH, J.; SALEH, H. M.; BROWN, A. Aplasia cutis congenita. In: STATPEARLS. Treasure Island: StatPearls Publishing, 2025. Available at: https://www.ncbi.nlm.nih.gov/books/NBK535403/. Accessed on: 10 Oct. 2026.

BULLO, M. *et al.* Pregnancy outcome following exposure to angiotensin-converting enzyme inhibitors or angiotensin receptor antagonists: a systematic review. Hypertension, v. 60, n. 2, p. 444-450, 2012. DOI: 10.1161/HYPERTENSIONAHA.112.196352. Available at: https://doi.org/10.1161/HYPERTENSIONAHA.112.196352. Accessed on: 15 Oct. 2026.

COI, A. *et al.* Epidemiology of aplasia cutis congenita: a population-based study in Europe. Journal of the European Academy of Dermatology and Venereology, v. 37, n. 3, p. 581-589, 2023. DOI: 10.1111/jdv.18690. Available at: https://doi.org/10.1111/jdv.18690. Accessed on: 11 Oct. 2026.

DHATTARWAL, N.; YADAV, N. Aplasia cutis congenita of the lumbosacral area with “hair collar sign” but no underlying neuroectodermal defects. Indian Journal of Paediatric Dermatology, v. 25, n. 1, p. 59-60, 2024. DOI: 10.4103/ijpd.ijpd_63_23. Available at: https://doi.org/10.4103/ijpd.ijpd_63_23. Accessed on: 11 Oct. 2026.

EL MOULOUA, A. *et al.* Aplasia cutis congenita of the trunk in a newborn: a rare case report. Pan African Medical Journal, v. 48, art. 52, 2024. DOI: 10.11604/pamj.2024.48.52.43784. Available at: https://doi.org/10.11604/pamj.2024.48.52.43784. Accessed on: 10 Oct. 2026.

FRIEDEN, I. J. Aplasia cutis congenita: a clinical review and proposal for classification. Journal of the American Academy of Dermatology, v. 14, n. 4, p. 646-660, 1986. Available at: https://pubmed.ncbi.nlm.nih.gov/3514708/. Accessed on: 10 Oct. 2026.

GARNE, E. *et al.* Spectrum of congenital anomalies in pregnancies with pregestational diabetes. Birth Defects Research Part A: Clinical and Molecular Teratology, v. 94, n. 3, p. 134-140, 2012. DOI: 10.1002/bdra.22886. Available at: https://doi.org/10.1002/bdra.22886. Accessed on: 10 Oct. 2026.

HUNSAKER, P. *et al.* Developmental abnormalities of the pediatric spine: a review of the correlation between ultrasound and MRI findings. Cureus, v. 15, n. 9, e44580, 2023. DOI: 10.7759/cureus.44580. Available at: https://doi.org/10.7759/cureus.44580. Accessed on: 11 Oct. 2026.

JIA, S. *et al.* Maternal, paternal, and neonatal risk factors for neural tube defects: a systematic review and meta-analysis. International Journal of Developmental Neuroscience, v. 78, p. 227-235, 2019. DOI: 10.1016/j.ijdevneu.2019.09.006. Available at: https://doi.org/10.1016/j.ijdevneu.2019.09.006. Accessed on: 10 Oct. 2026.

KRISS, V. M.; DESAI, N. S. Occult spinal dysraphism in neonates: assessment of high-risk cutaneous stigmata on sonography. American Journal of Roentgenology, v. 171, n. 6, p. 1687-1692, 1998. Available at: https://pubmed.ncbi.nlm.nih.gov/9843314/. Accessed on: 10 Oct. 2026.

RILEY, D. S. *et al.* CARE guidelines for case reports: explanation and elaboration document. Journal of Clinical Epidemiology, v. 89, p. 218-235, 2017. DOI: 10.1016/j.jclinepi.2017.04.026. Available at: https://doi.org/10.1016/j.jclinepi.2017.04.026. Accessed on: 10 Oct. 2026.

SEWELL, M. J.; CHIU, Y. E.; DROLET, B. A. Neural tube dysraphism: review of cutaneous markers and imaging. Pediatric Dermatology, v. 32, n. 2, p. 161-170, 2015. DOI: 10.1111/pde.12485. Available at: https://doi.org/10.1111/pde.12485. Accessed on: 11 Oct. 2026.

SHIELDS, L. B. *et al.* Risk of occult spinal dysraphism based on lumbosacral cutaneous manifestations. SAGE Open Medicine, v. 9, 20503121211037172, 2021. DOI: 10.1177/20503121211037172. Available at: https://doi.org/10.1177/20503121211037172. Accessed on: 11 Oct. 2026.

SVOKOS, K. *et al.* International survey on the management of lumbosacral cutaneous stigmata in infants with suspected occult spinal dysraphism. Journal of Neurosurgery: Pediatrics, v. 28, n. 5, p. 592-599, 2021. DOI: 10.3171/2021.5.PEDS2126. Available at: https://doi.org/10.3171/2021.5.PEDS2126. Accessed on: 10 Oct. 2026.

VETRANO, I. G. *et al.* Multidisciplinary management of children with occult spinal dysraphism: a comprehensive journey from birth to adulthood. Children, v. 9, n. 10, 1546, 2022. DOI: 10.3390/children9101546. Available at: https://doi.org/10.3390/children9101546. Accessed on: 10 Oct. 2026.